

NEUROIMAGING

(...at the NIH)

Peter A. Bandettini, Ph.D.

Functional MRI Facility
Unit on Functional Imaging Methods
Laboratory of Brain and Cognition

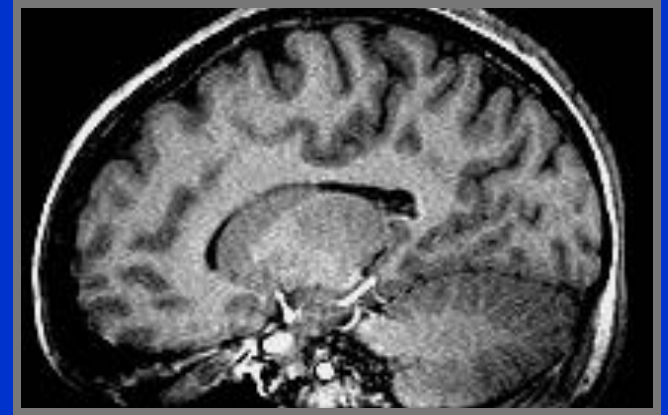


Two Types of Neuroimaging

- Structural/Anatomical Imaging
- Functional Imaging

Structural Brain Imaging

- Reveals the anatomy of the brain and the physical structure of brain pathology.



- Primarily associated with Computerized Axial Tomography (CAT or CT) and Magnetic Resonance Imaging (MRI).

- **Structural/Anatomical Imaging**
 - X-ray
 - Computerized Tomography (CT)
 - Magnetic Resonance Imaging (MRI)
 - Angiography
 - Venography
 - Perfusion
 - Diffusion Tensor Imaging

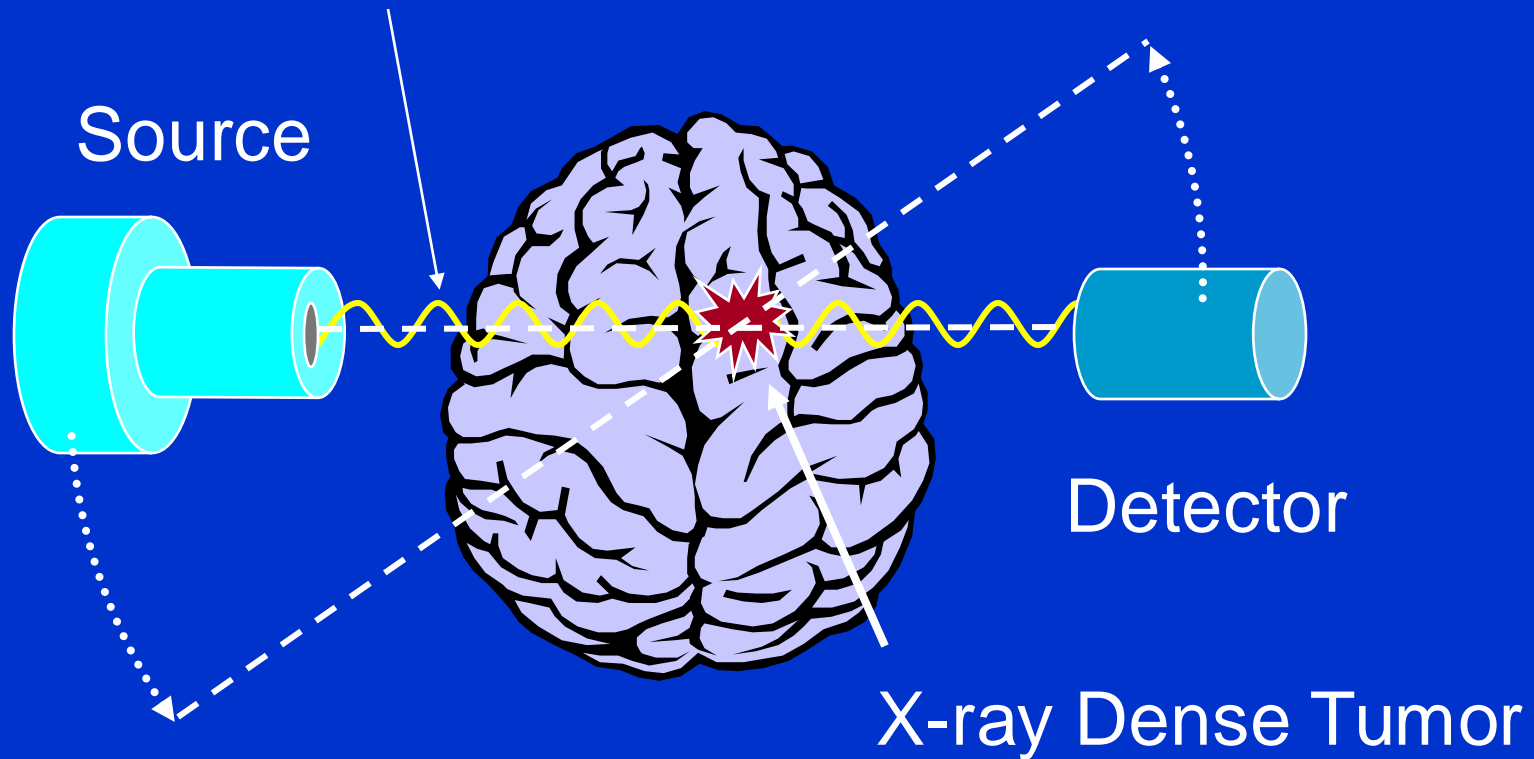
•Functional Imaging

- Xenon Computerized Tomography (Xe CT)
- Positron Emission Tomography (PET)
- Single Photon Computed Tomography (SPECT)
- Functional MRI (fMRI)
- Electroencephalography (EEG)
- Magnetoencephalography (MEG)
- Transcranial Magnetic Stimulation (TMS)

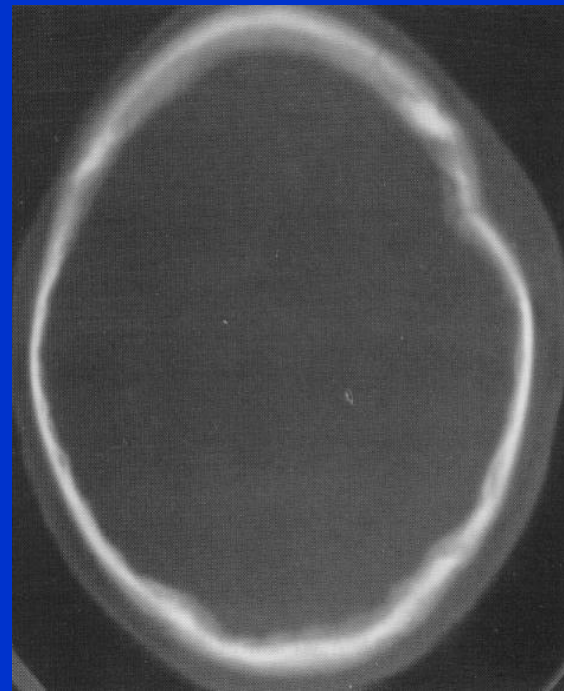
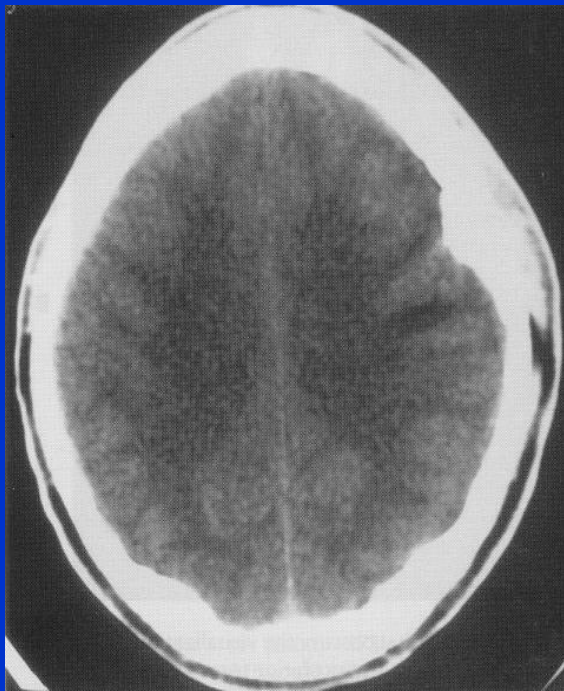Computerized Tomography (CT)

Creation of images in slices or sections.

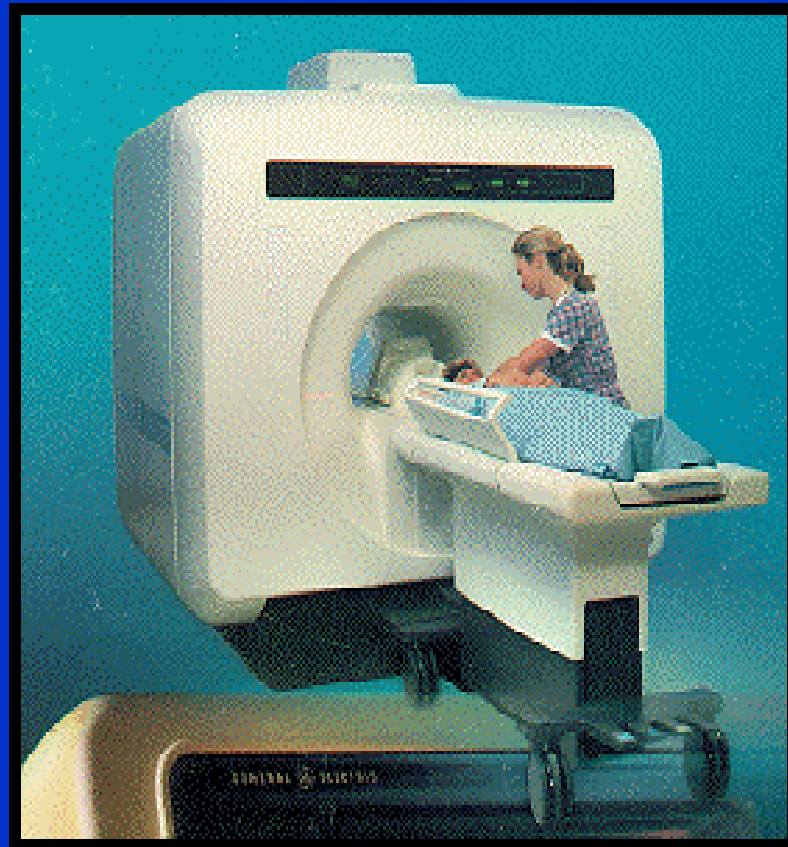
Narrow X-ray beam



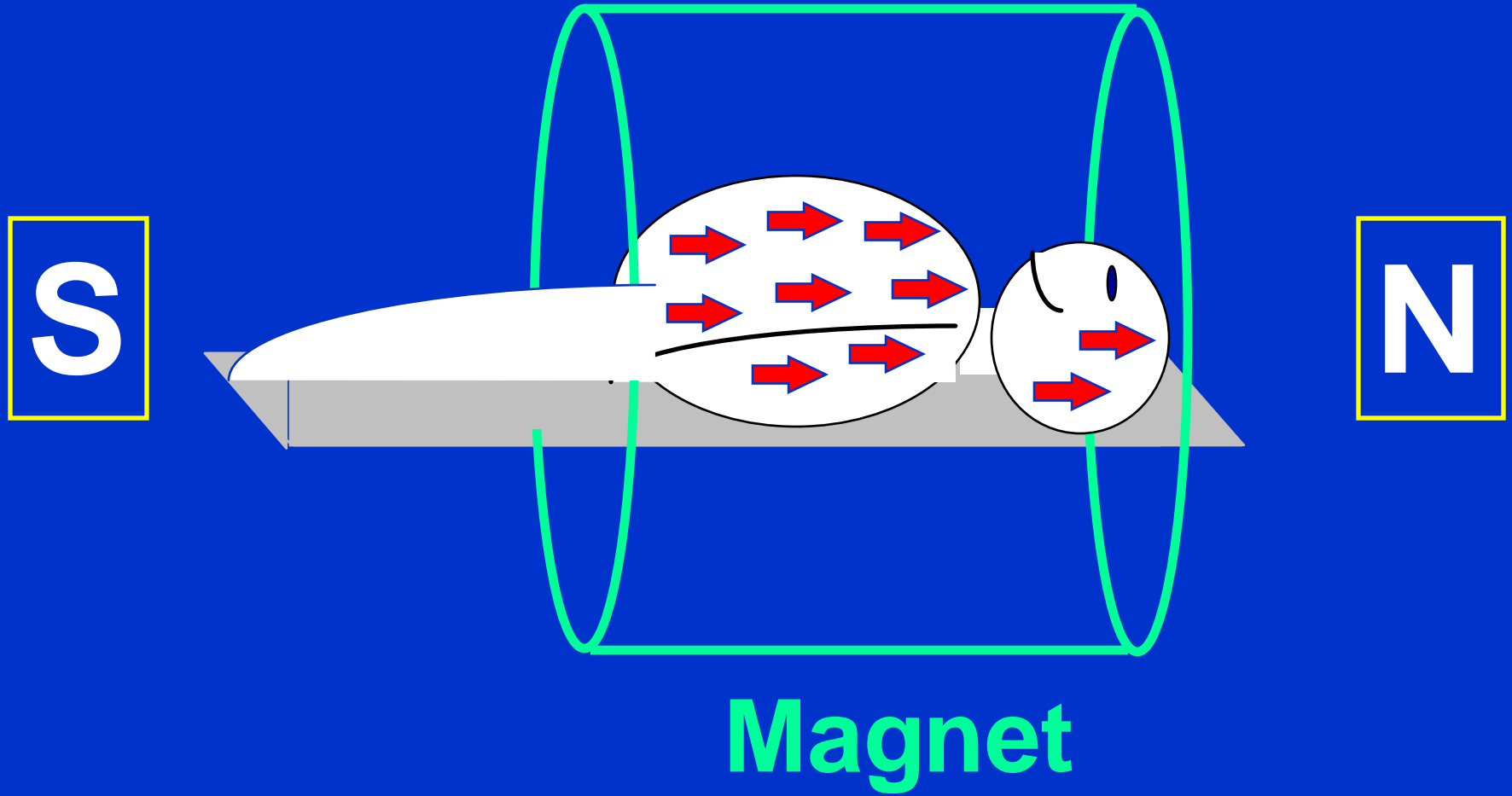
CT Images



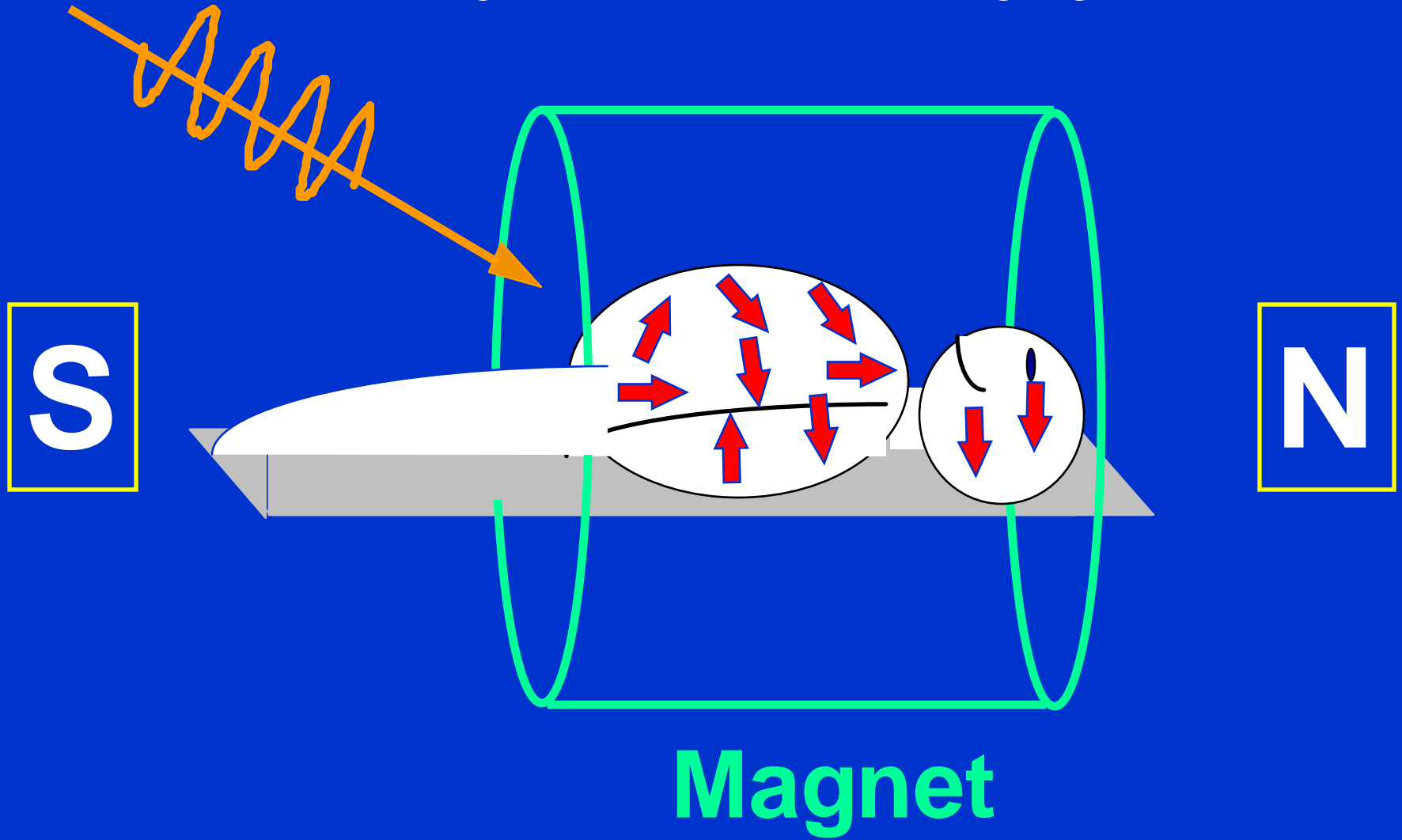
Magnetic Resonance Imaging



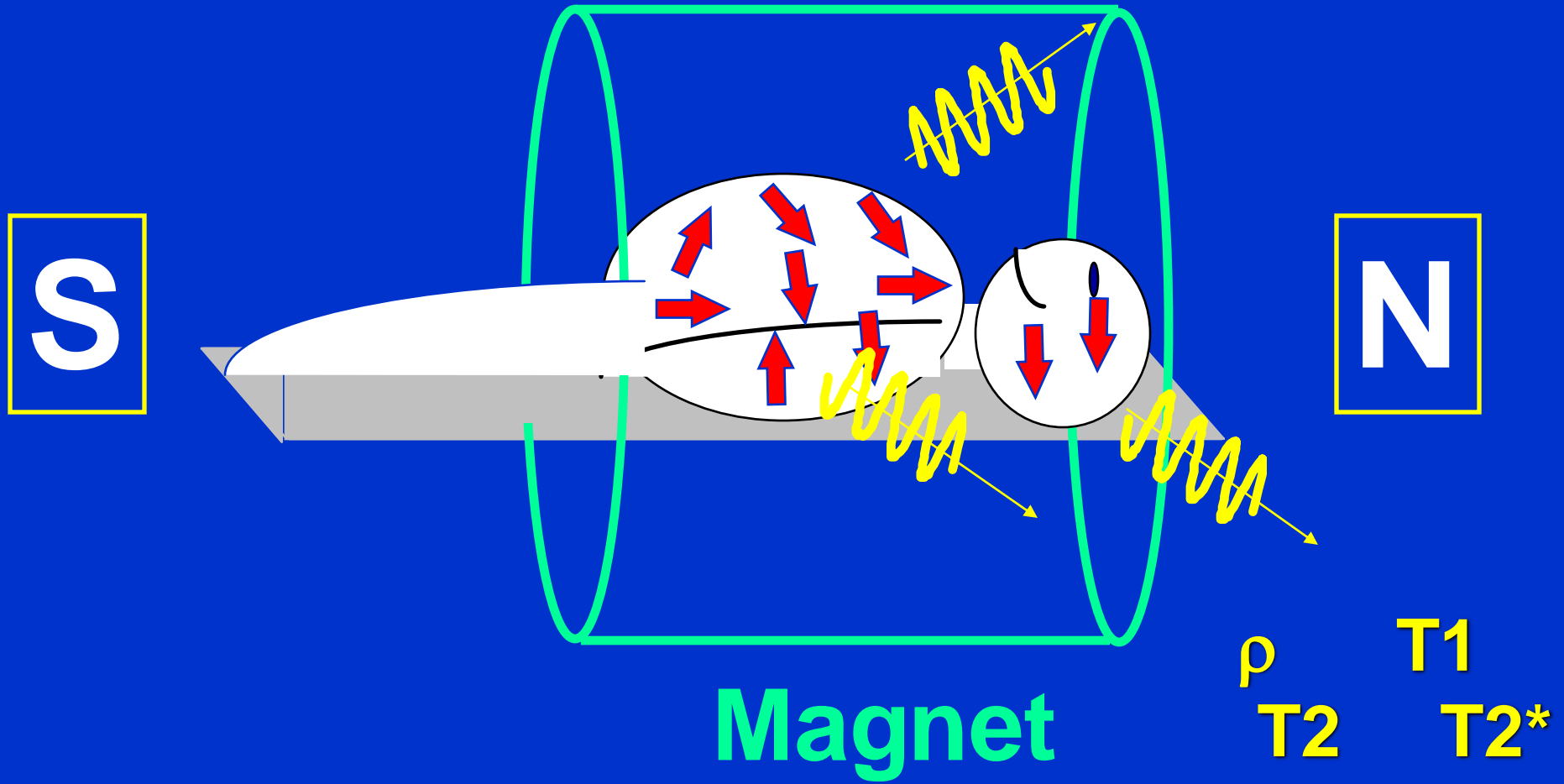
Magnetic Resonance Imaging



Magnetic Resonance Imaging

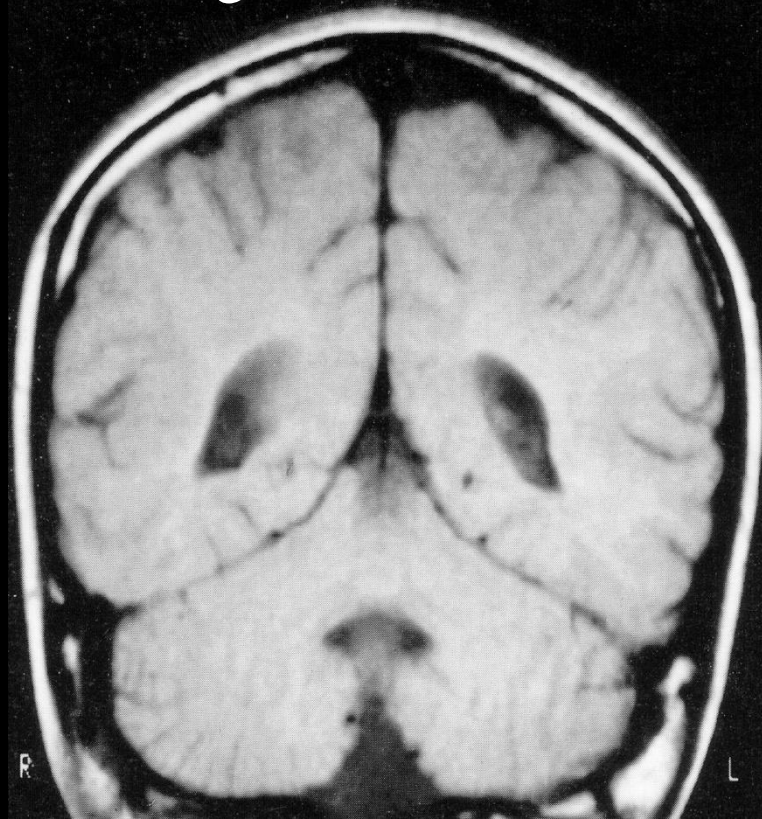


Magnetic Resonance Imaging

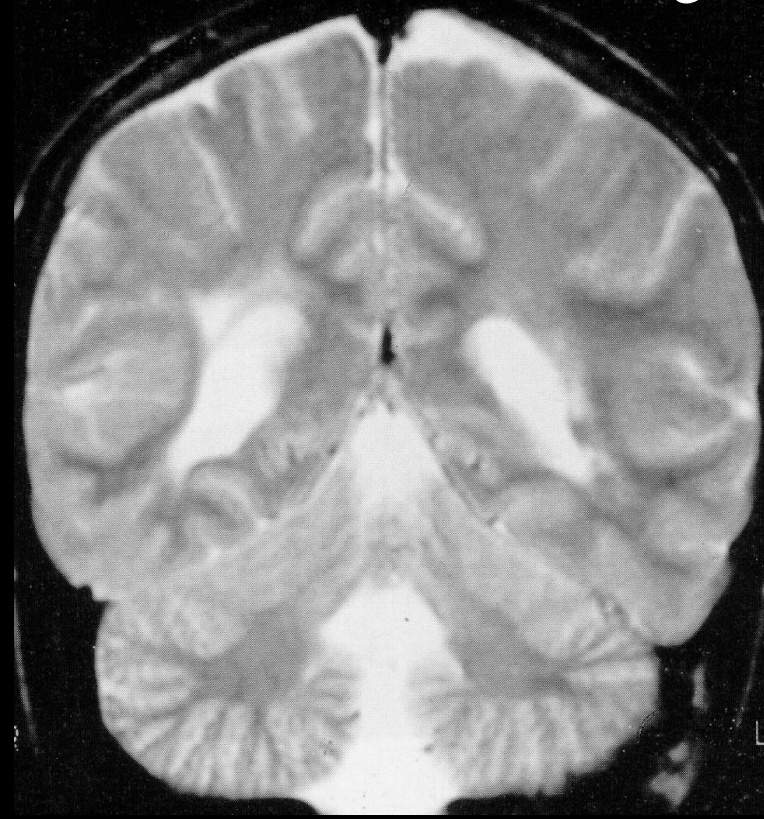


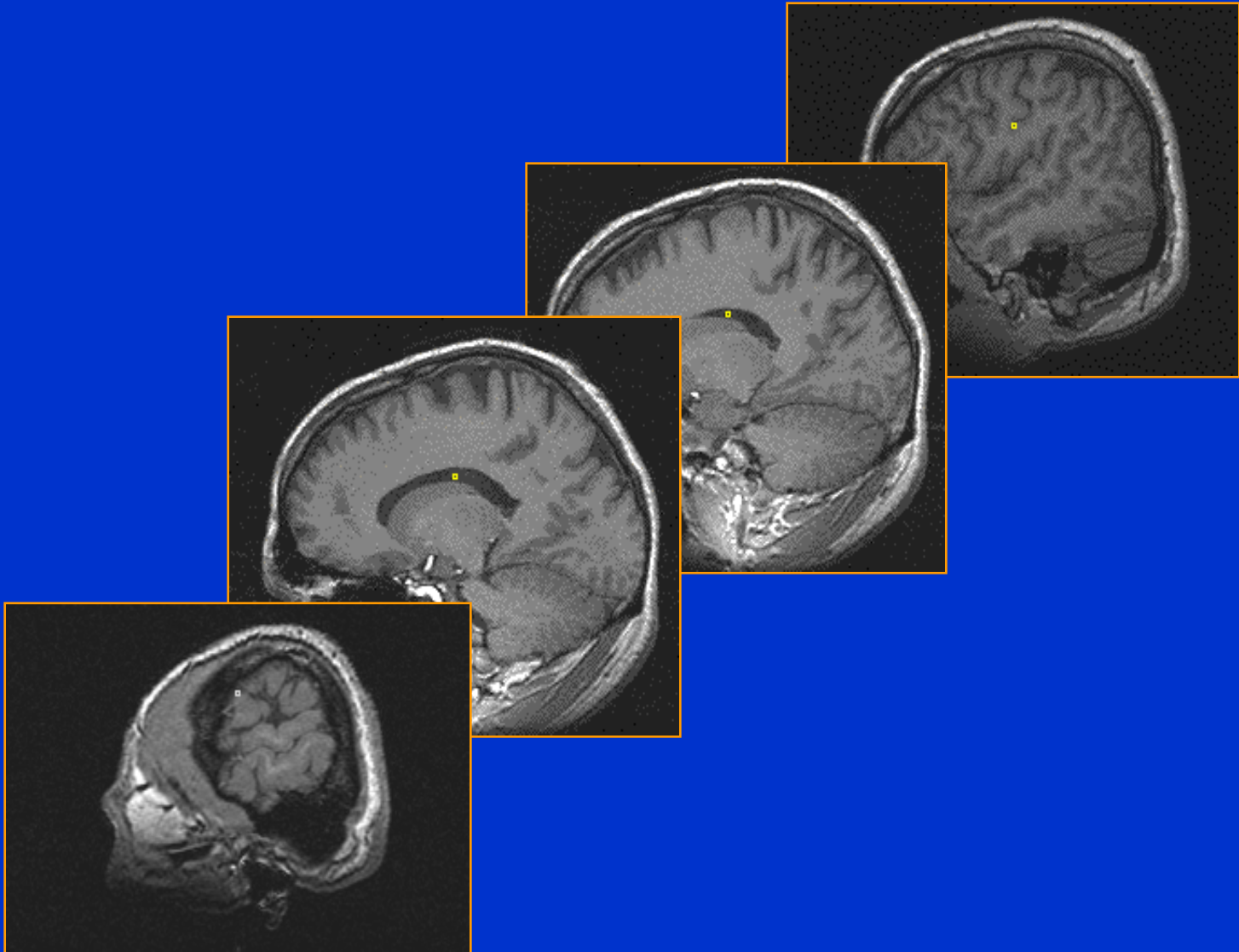
MRI Images with Different Contrast Weighting

T1 Weighted

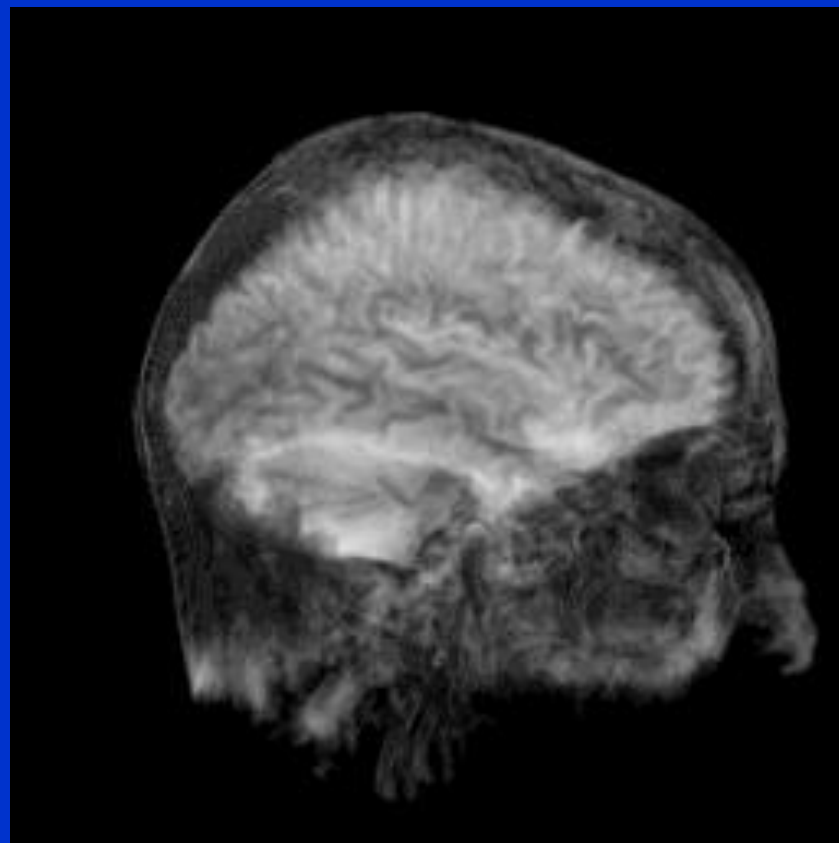
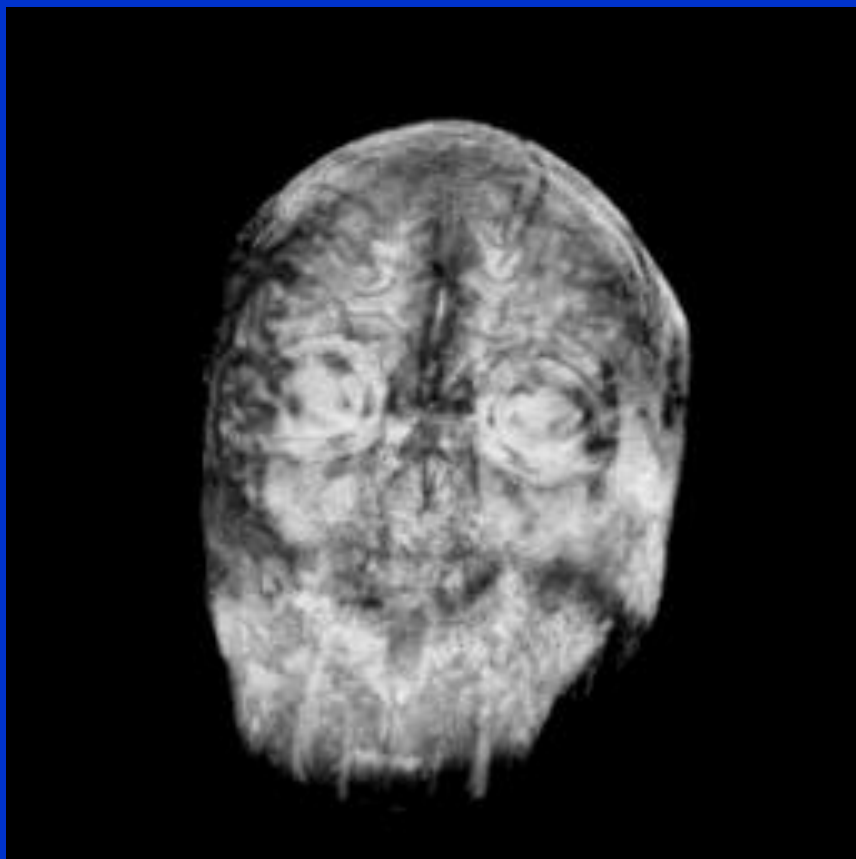


T2 Weighted



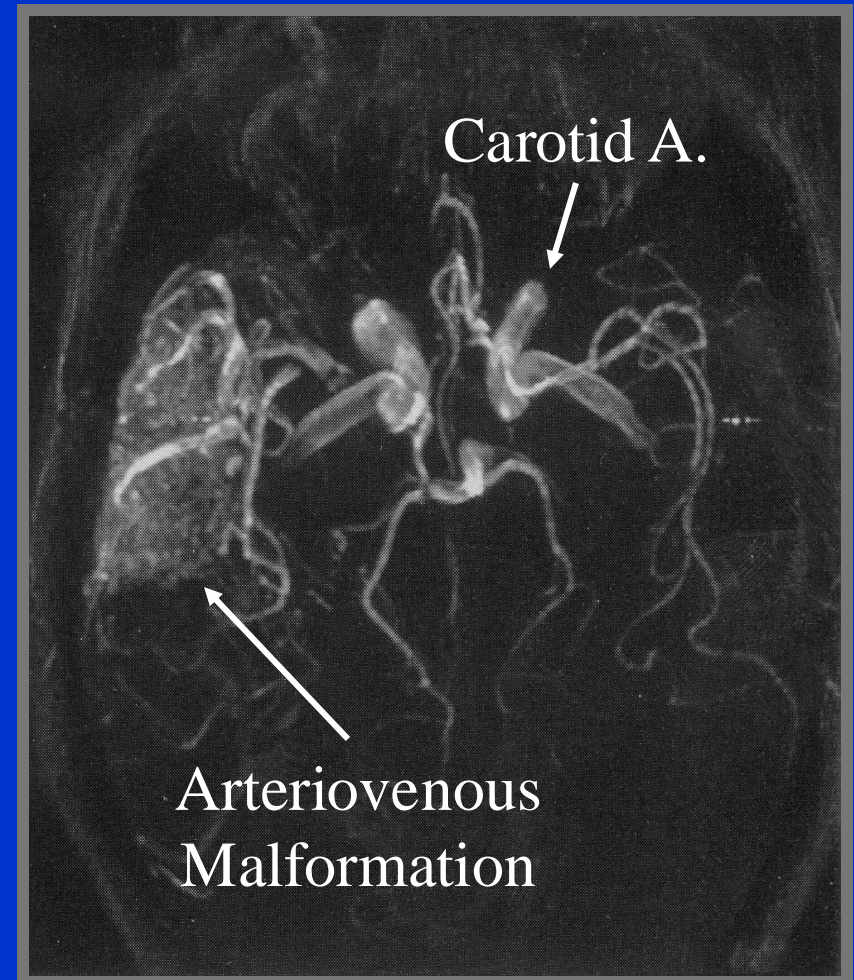
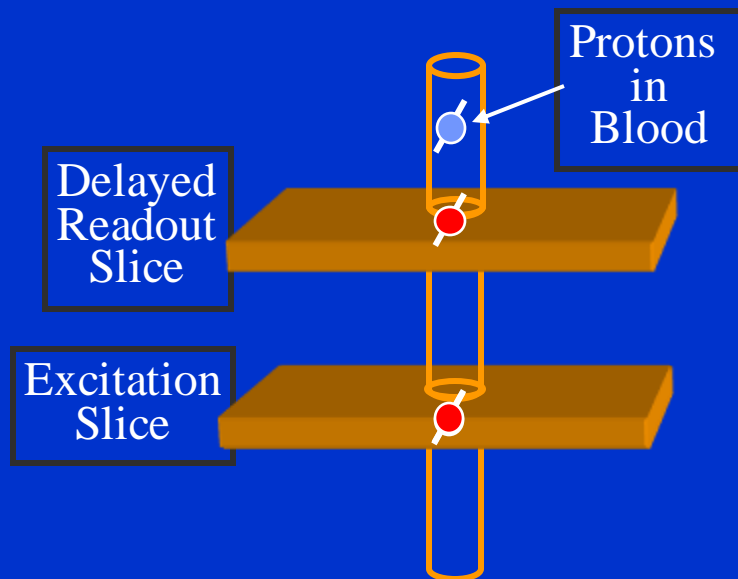


3D Rendered MRI

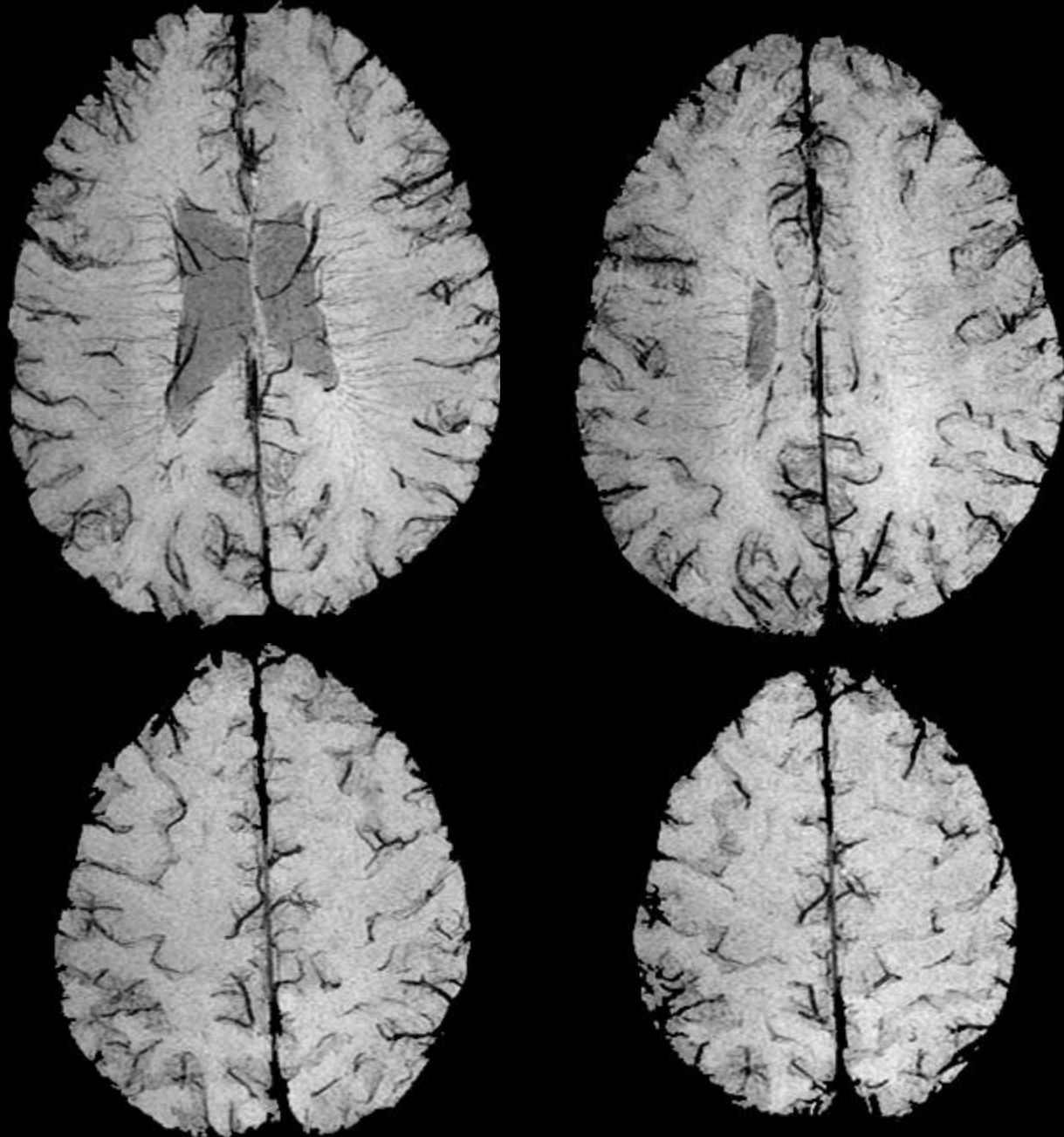


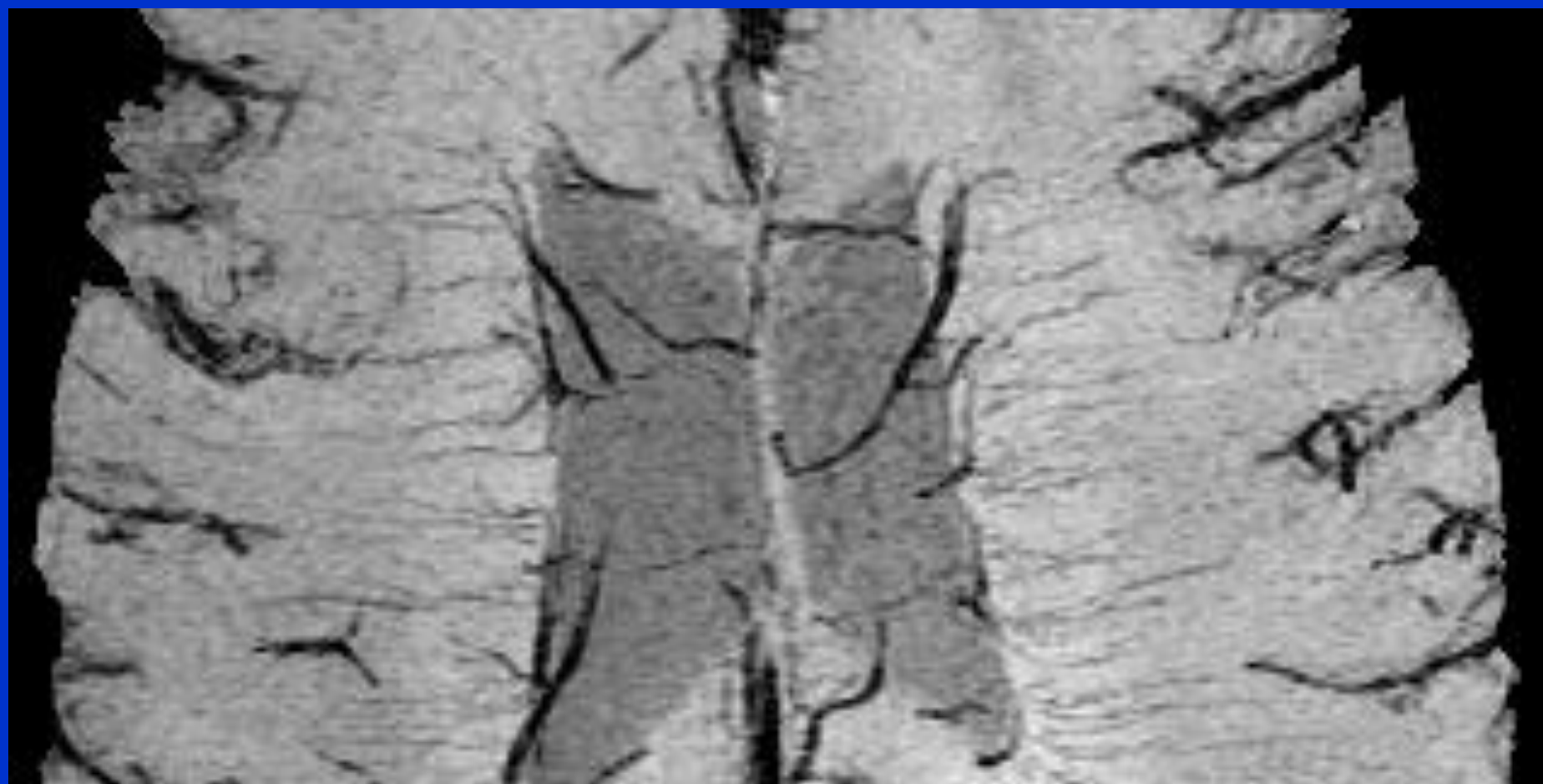MR Angiography Shows Blood Vessel Structure

- Blood vessel structure can be visualized by injection of MR tracers or by “spin tagging” techniques.



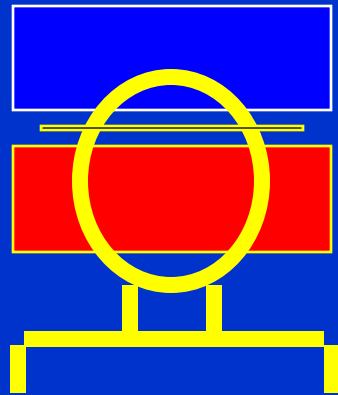
Venograms (3T)








Perfusion / Flow Imaging

EPISTAR

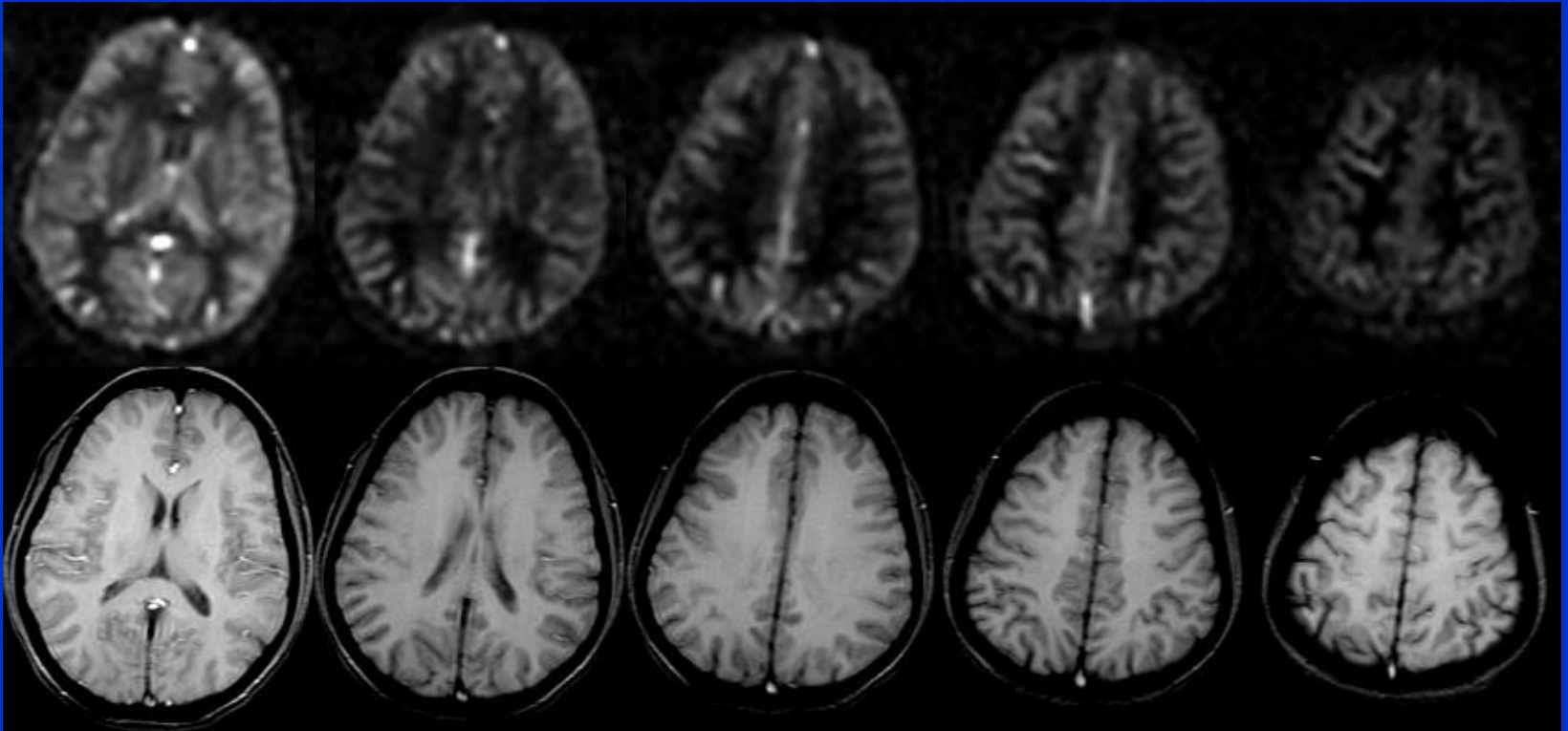


FAIR

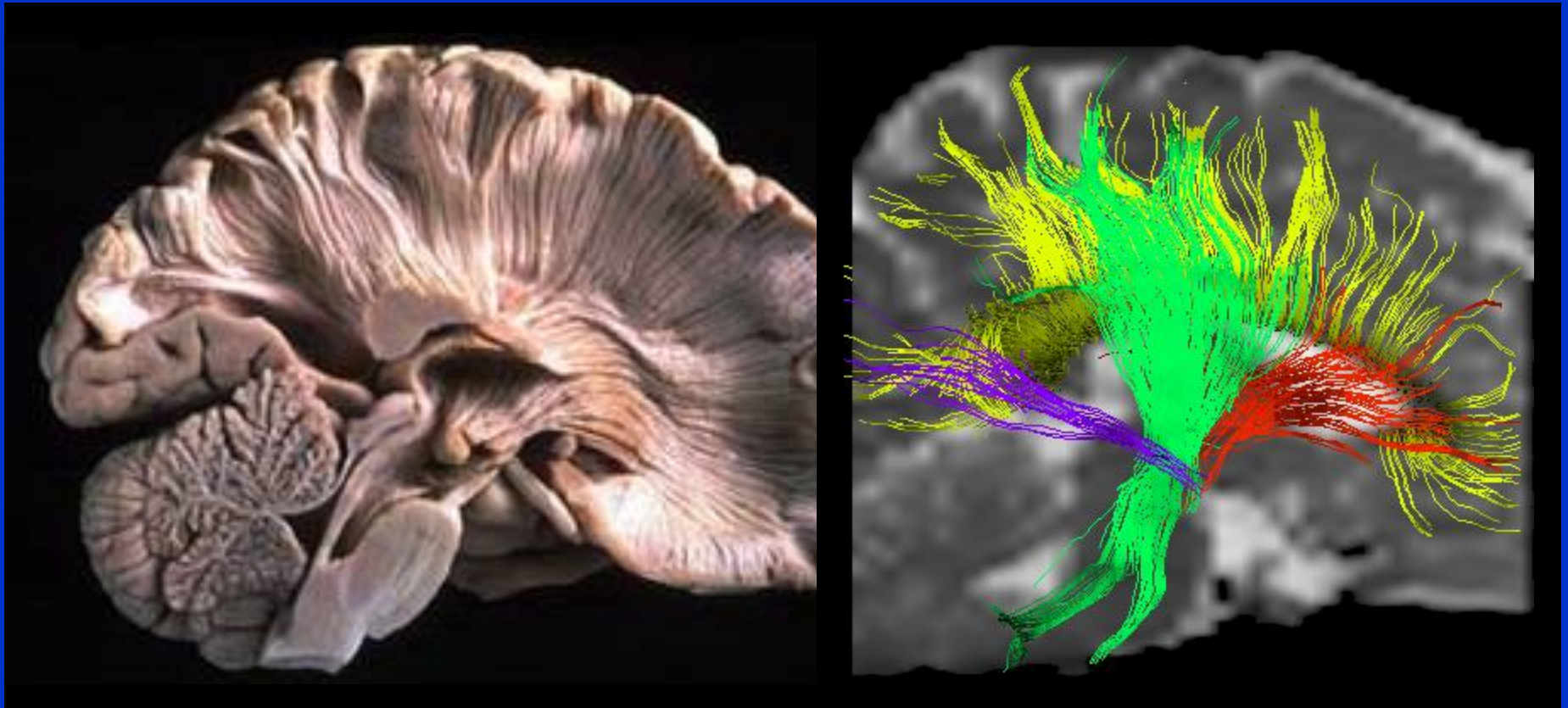


Perfusion
Time Series

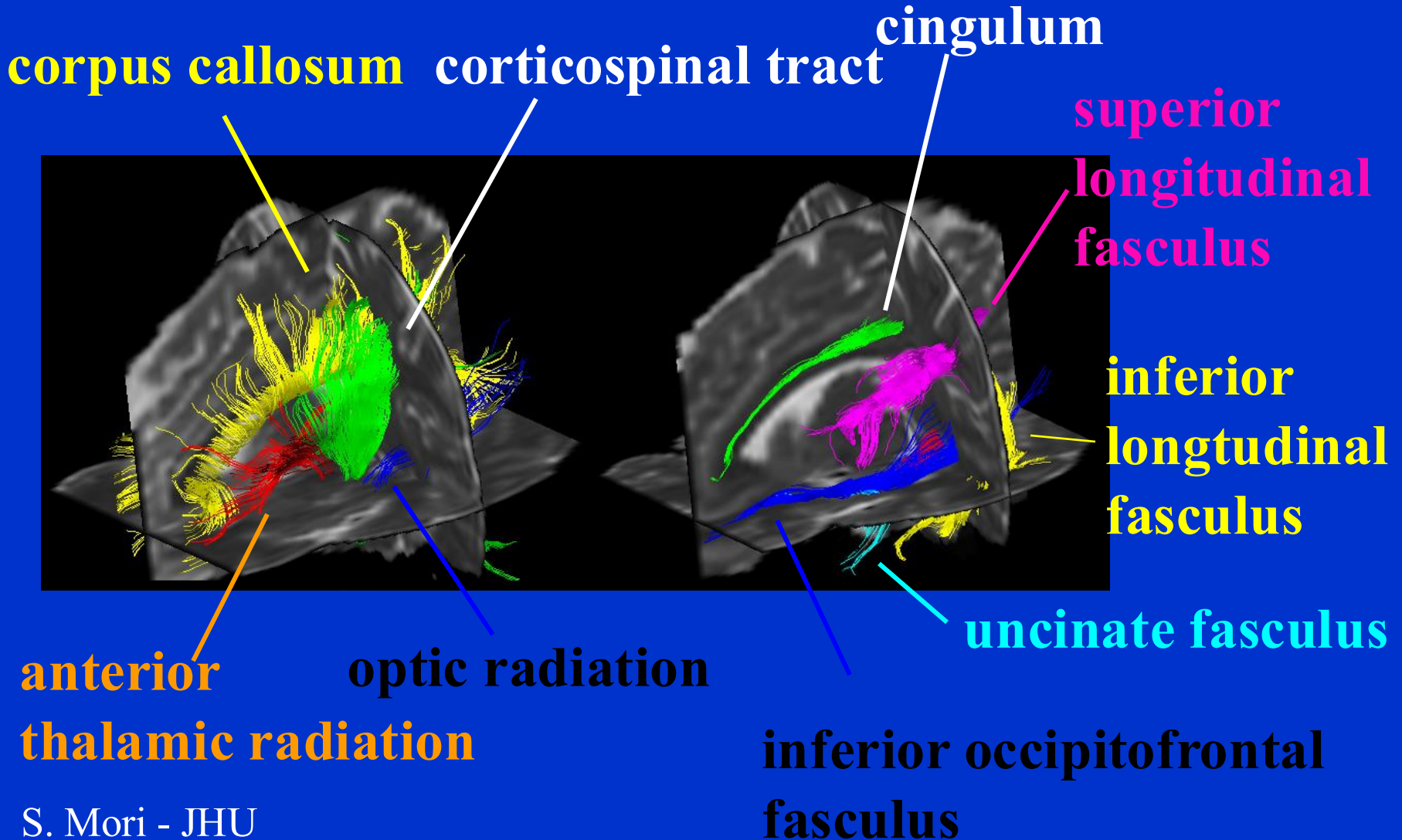
Perfusion Imaging with MRI



Diffusion Tensor Imaging

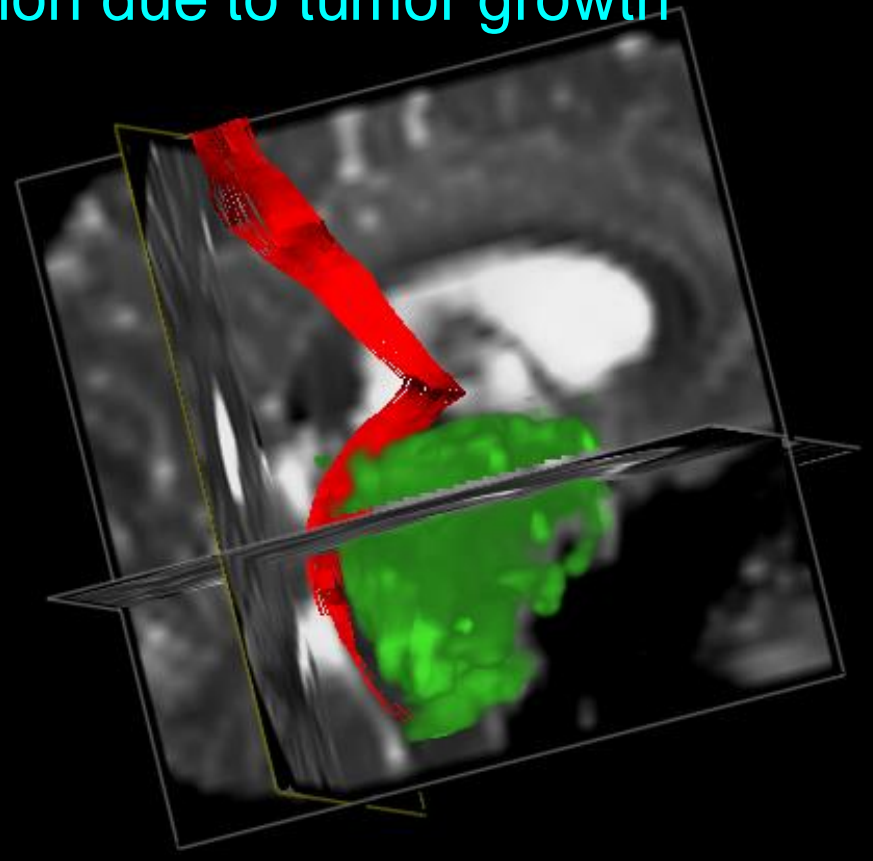
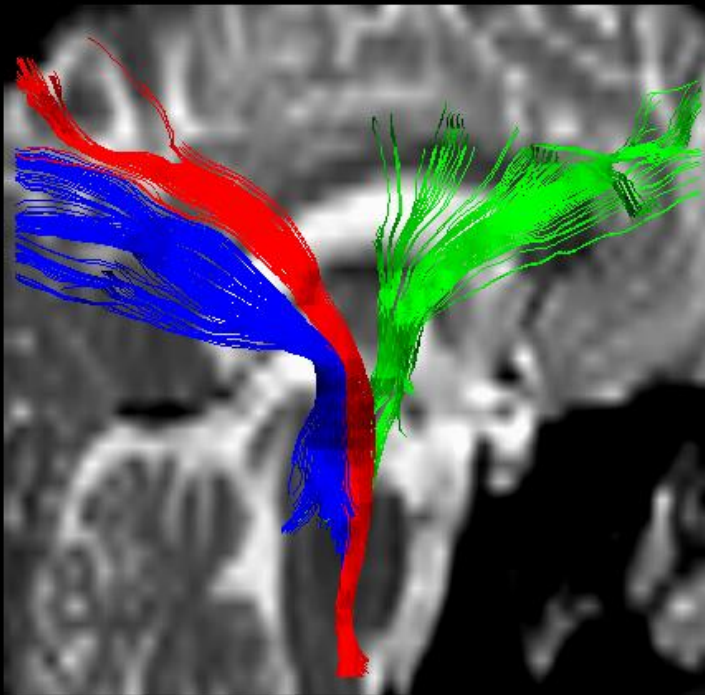


Diffusion Tensor Imaging

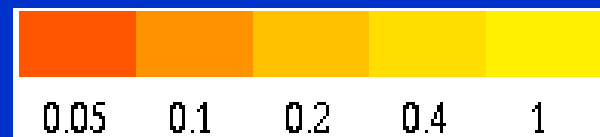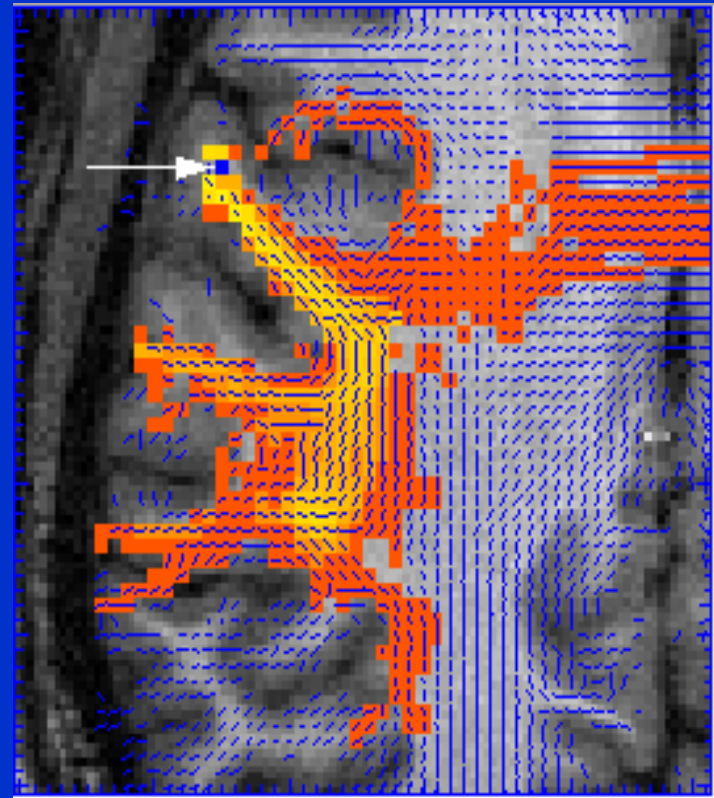



Anatomical guidance with DTI:

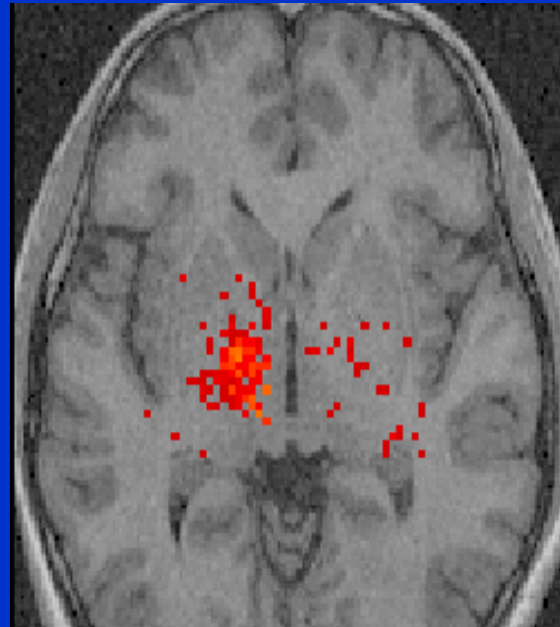
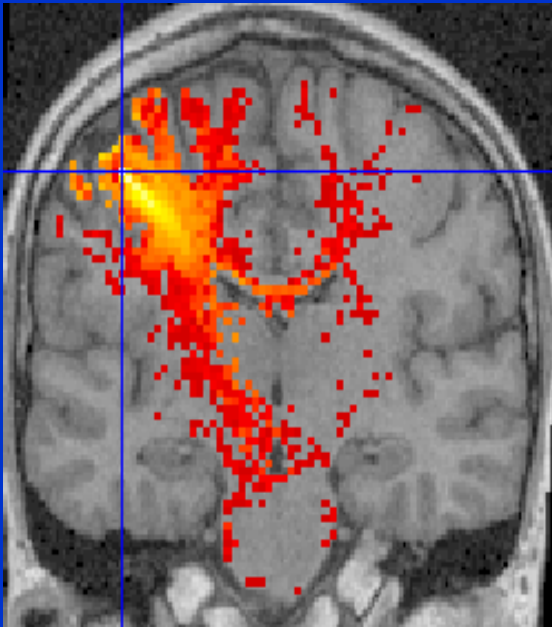
Example: Anatomical deformation due to tumor growth



DTI Connectivity



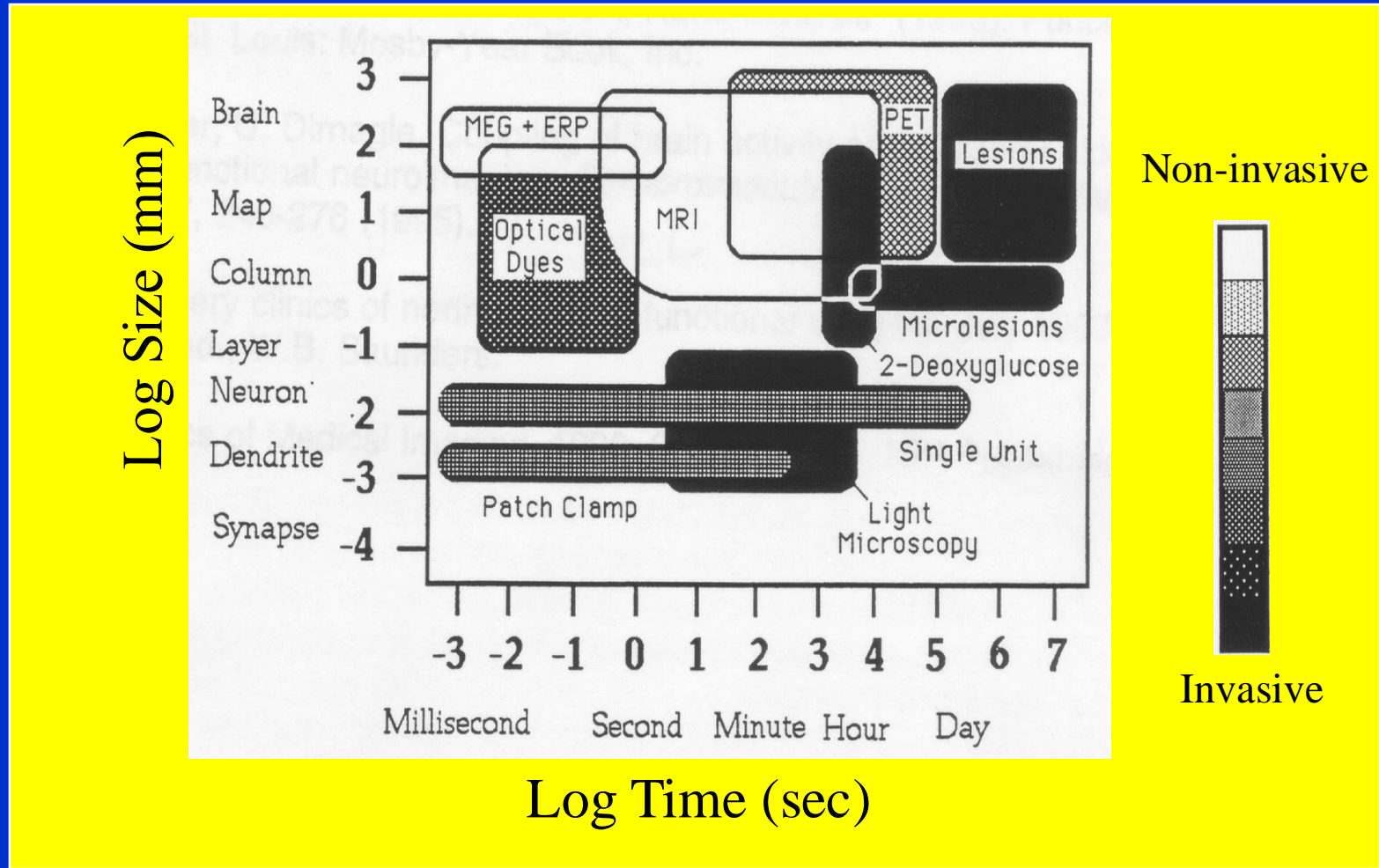
DTI Connectivity



Functional Imaging

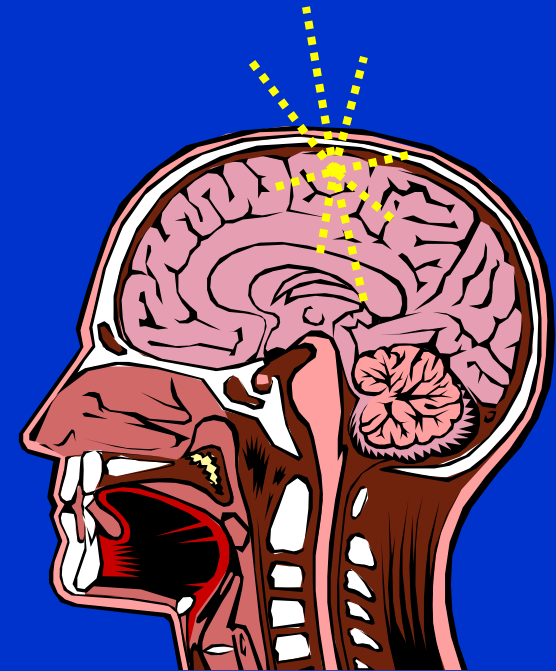
- Unlike structural imaging, functional imaging provides pictures of brain physiology or chemistry.
- By targeting factors that are related to brain activity (eg. blood flow and oxygenation), images of brain activation can be obtained.
- Functional imaging has been used for pre-surgical mapping of function and, eventually, may replace or augment more traditional tests.
- Functional imaging is now a major new research paradigm in neuroscience.

Functional Neuroimaging Techniques

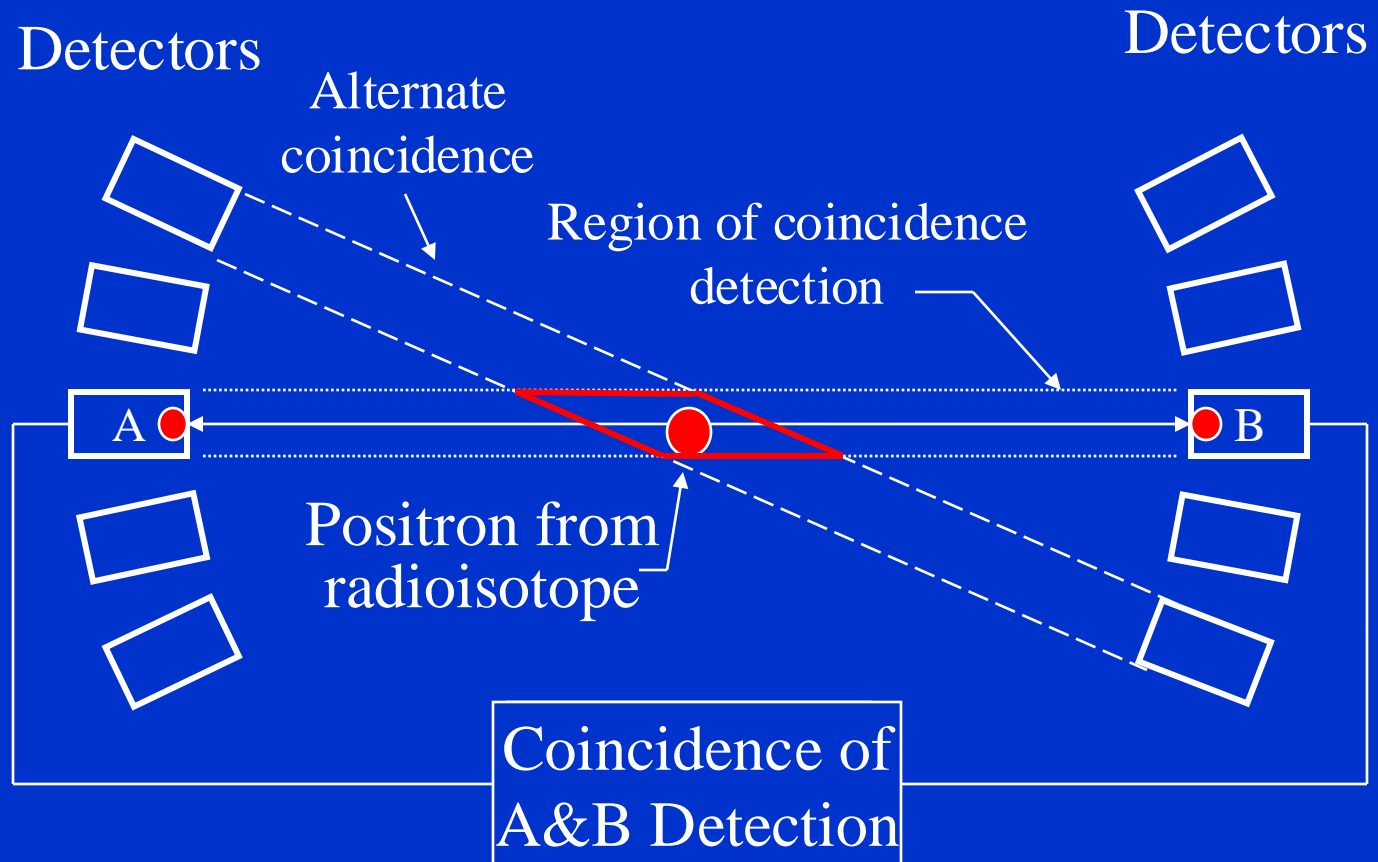


Positron Emission Tomography (PET)

- Positron emission tomography (PET) is a technique for studying functional processes *in vivo* by measuring the concentrations of positron-emitting radioisotopes within the subject.
- PET is primarily used to study biochemical and physiological processes within living organs with 3-dimensional spatial resolution.



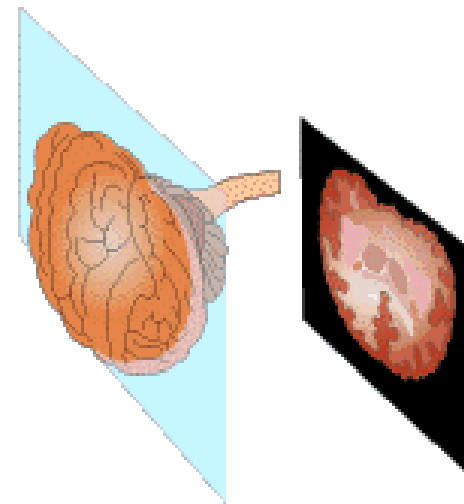
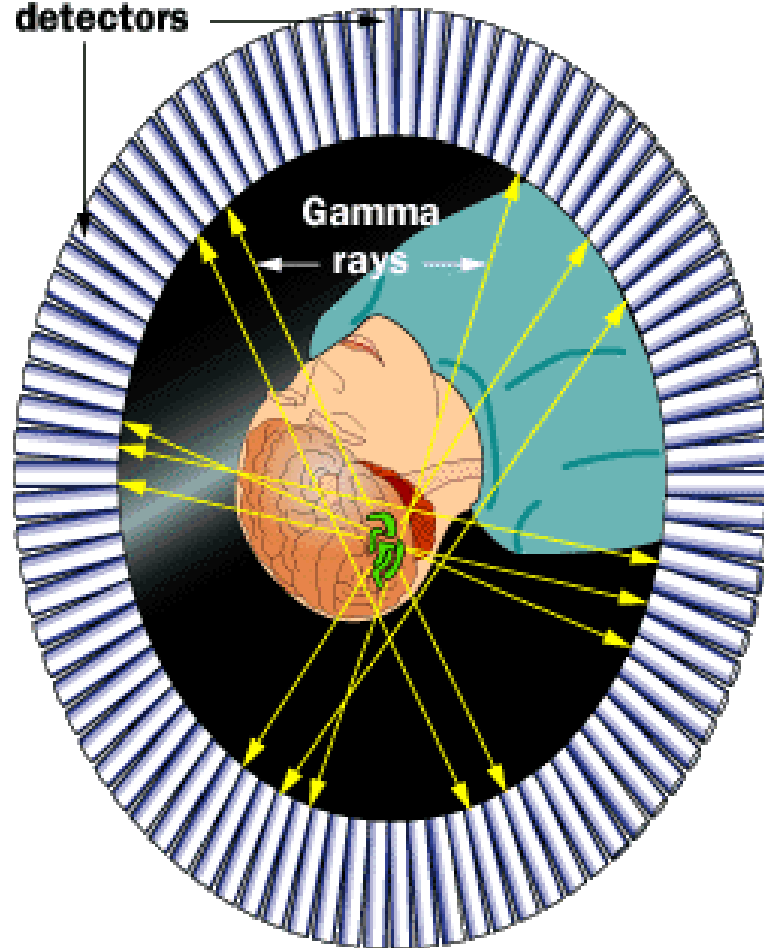
PET mechanism

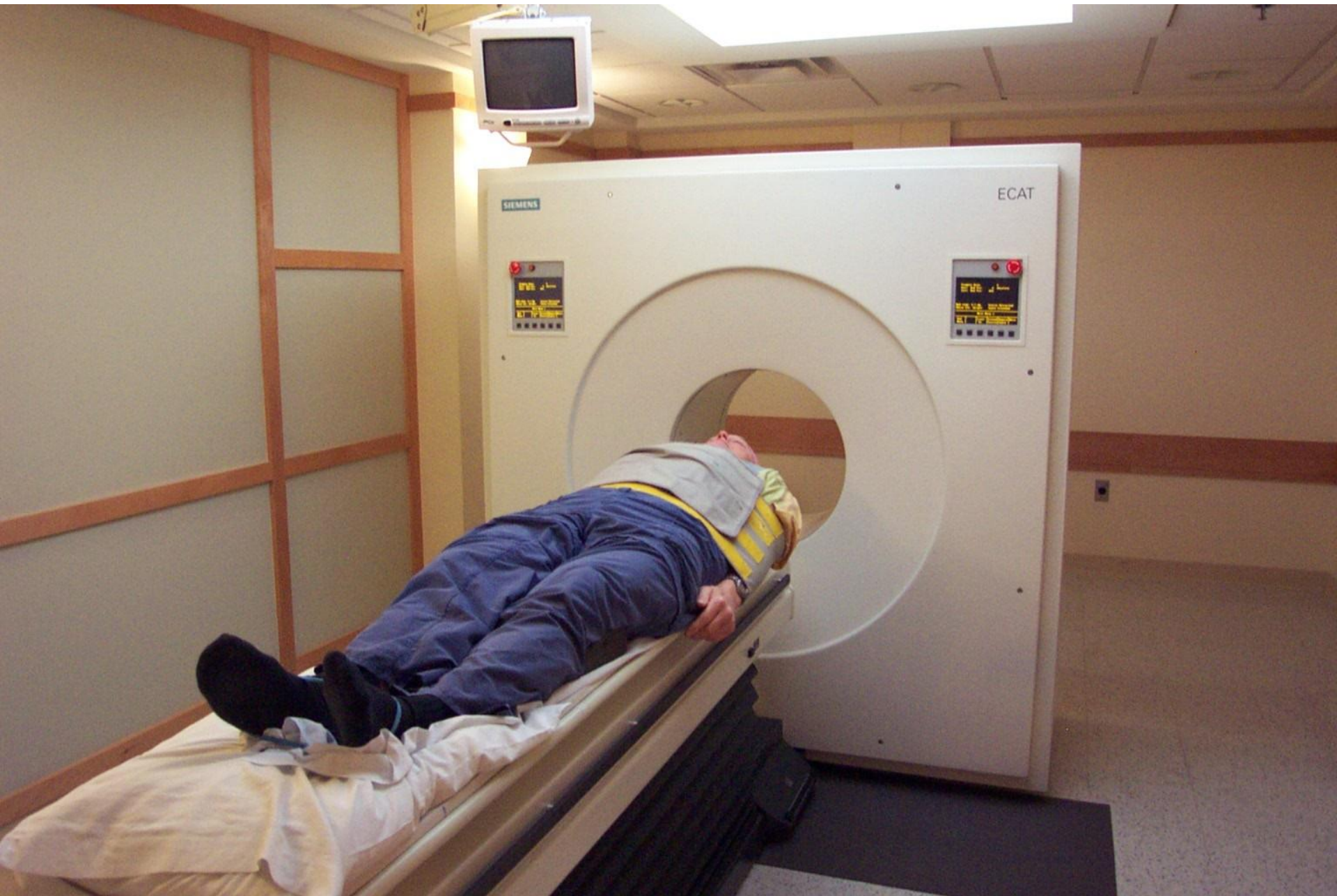

Positron Emission Tomography



Gamma ray detectors

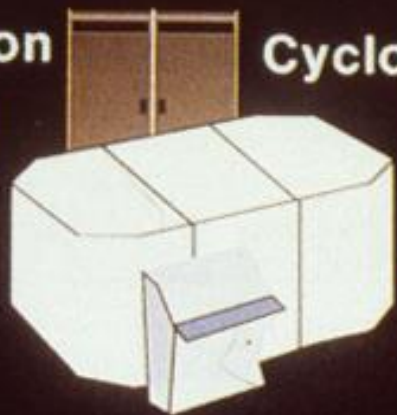




Imaging of neuroreceptors by PET

Isotope production

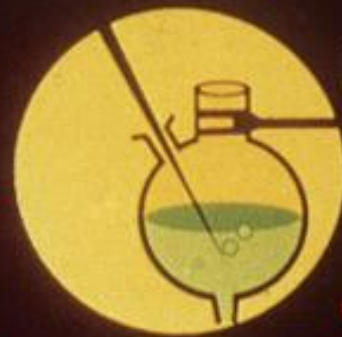[^{11}C ^{18}F ^{13}N ^{15}O]



Cyclotron

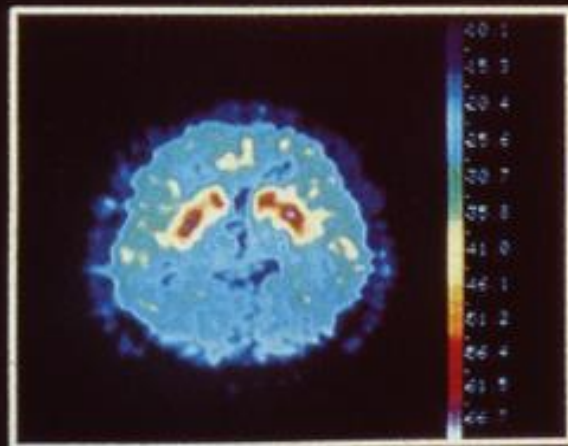
$^{11}\text{CO}_2$

Radio chemistry




Precursor

Image of
ligand distribution
in brain

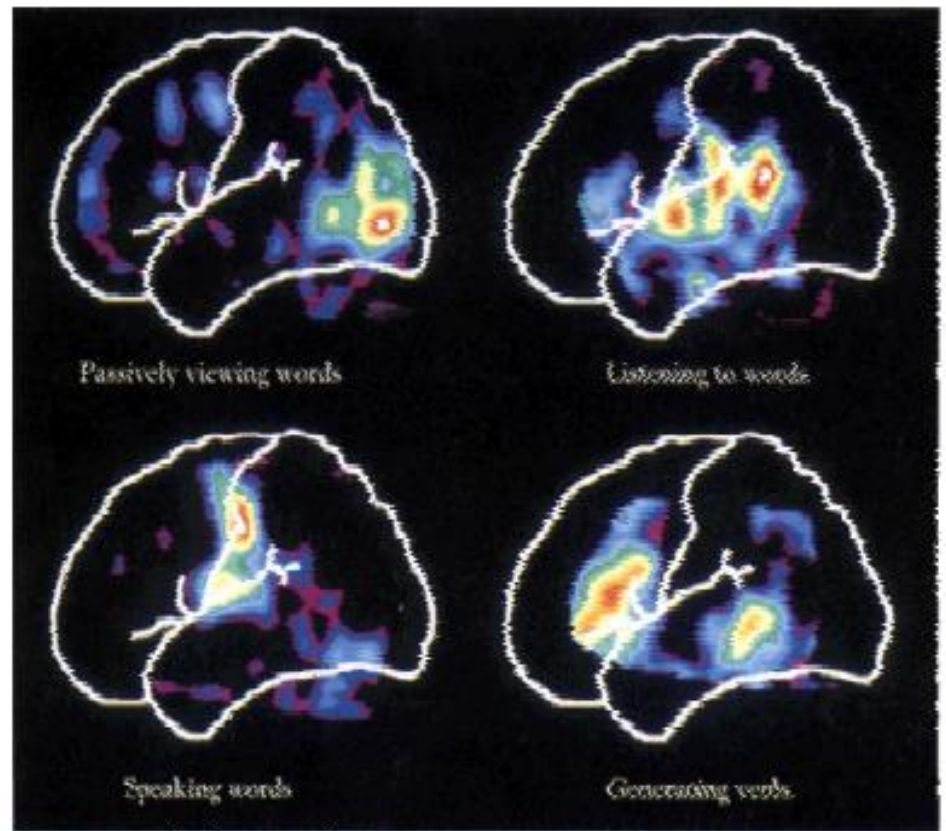
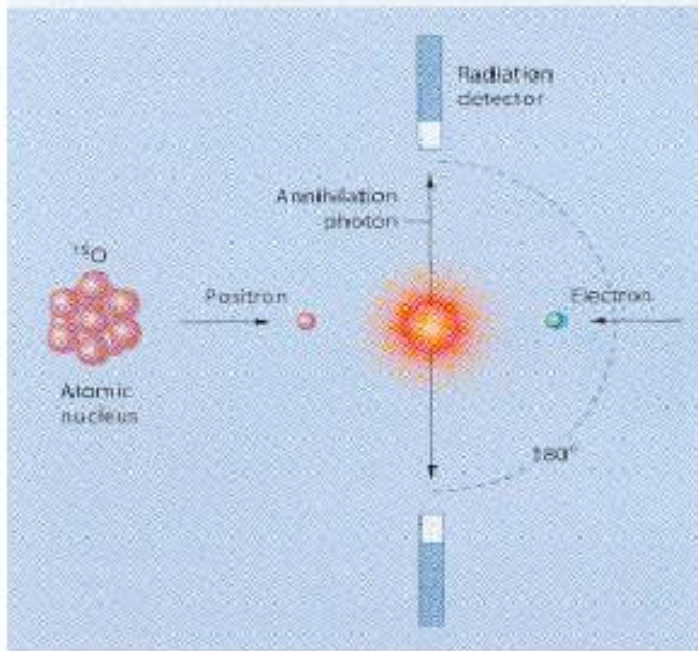
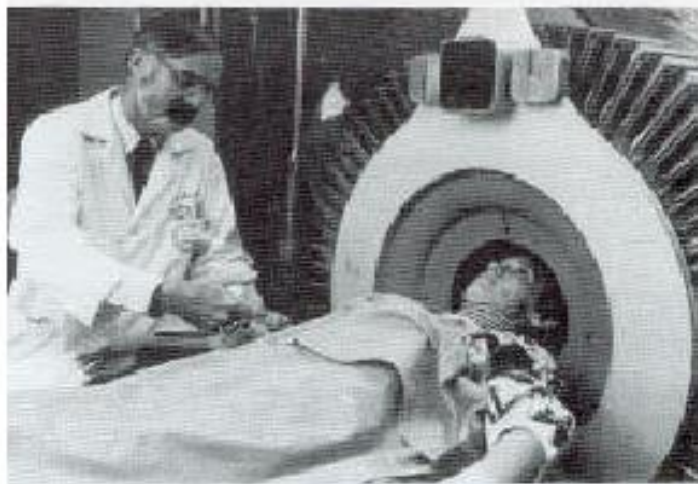

Positron camera

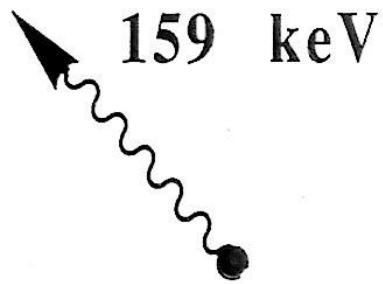


^{11}C -ligand





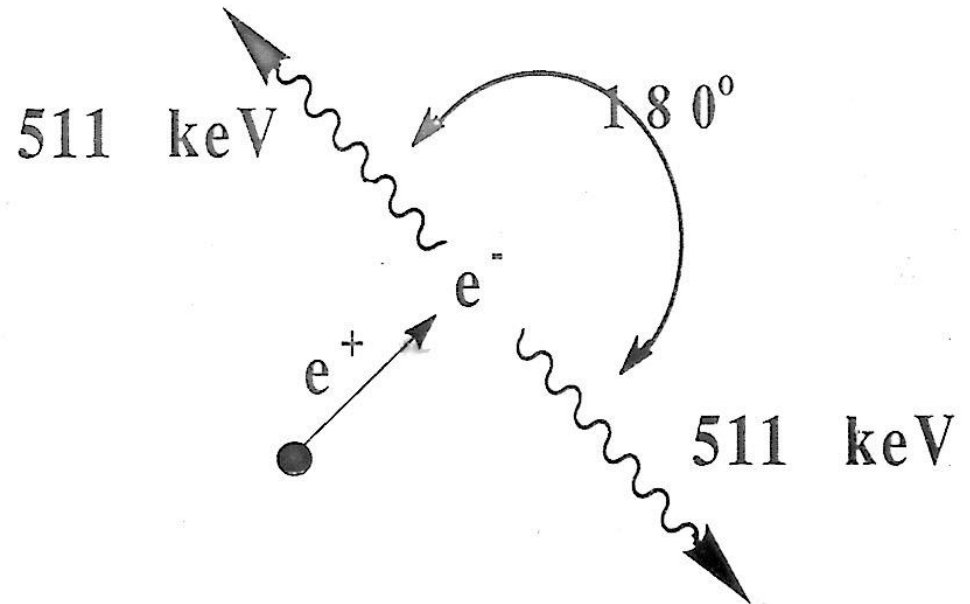
SPECT



Single Photon

Source ^{123}I

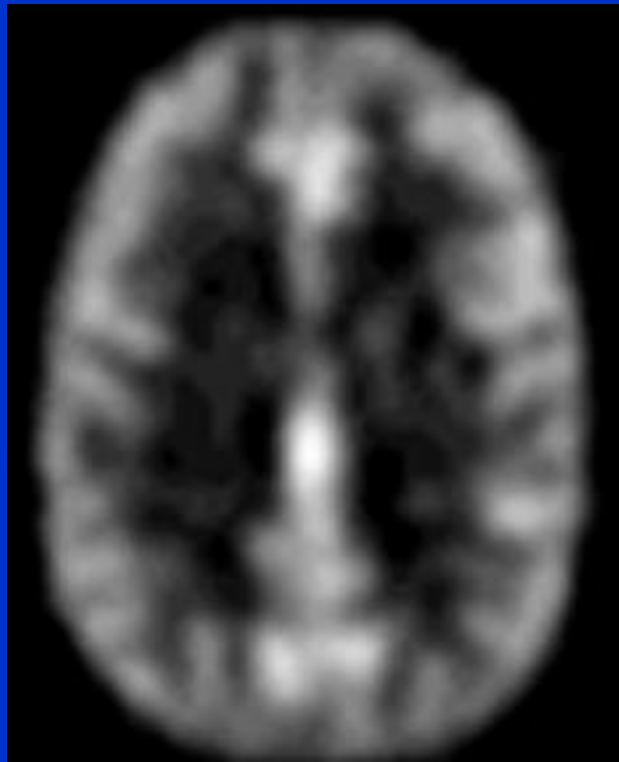
PET



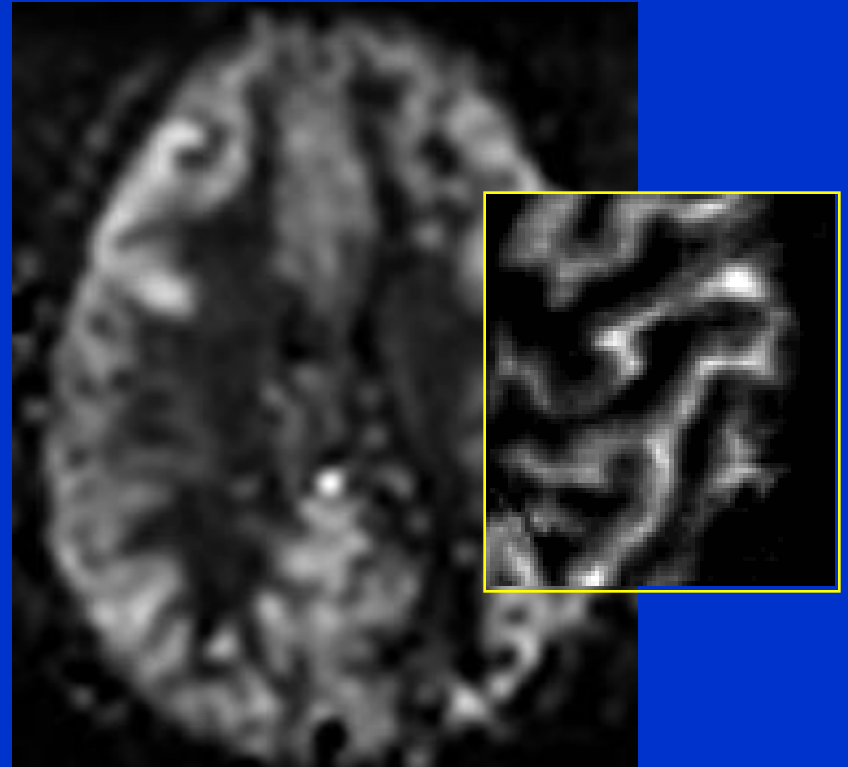
Positron Source

Comparison with Positron Emission Tomography

Emission Tomography

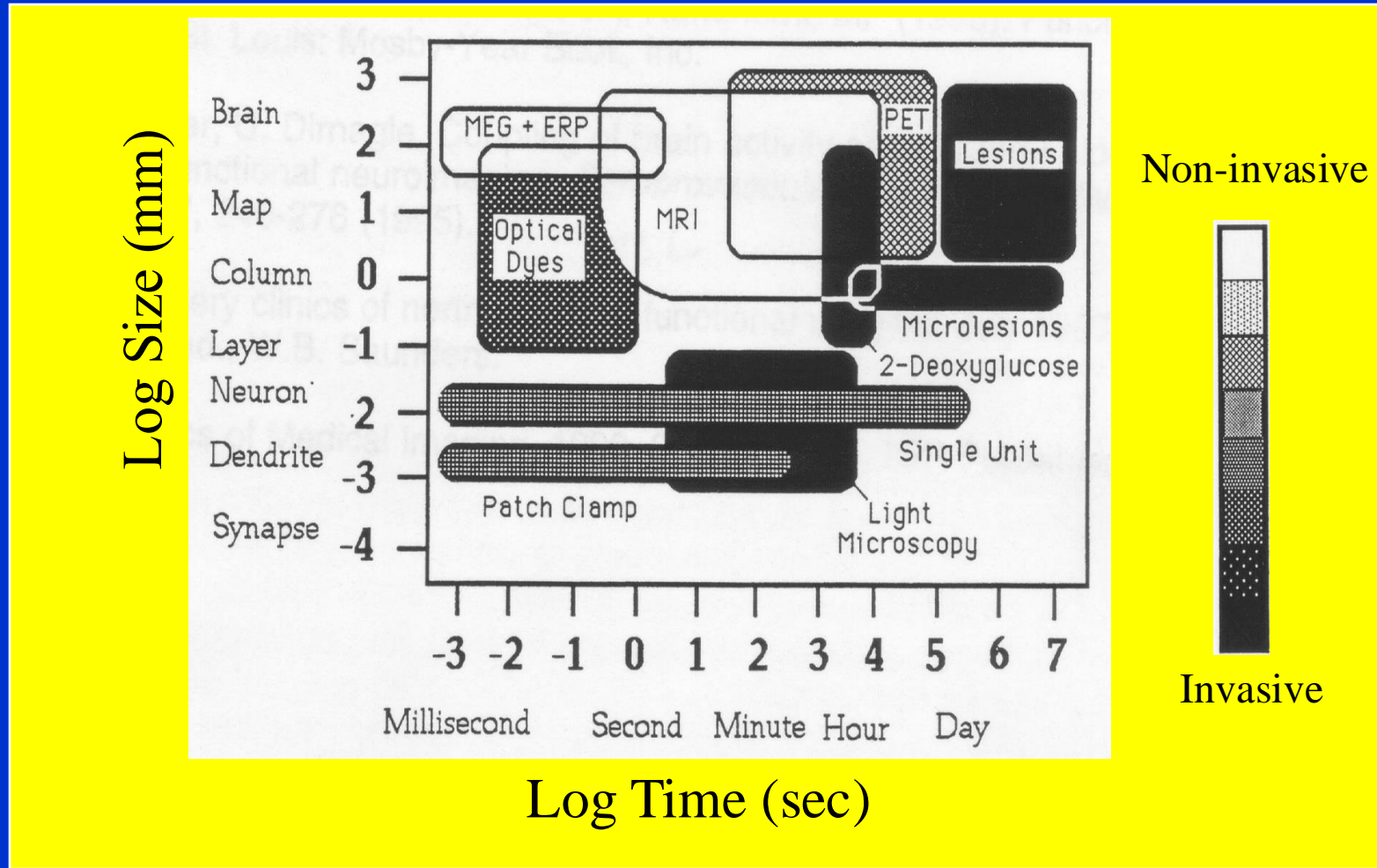


PET: H_2^{15}O



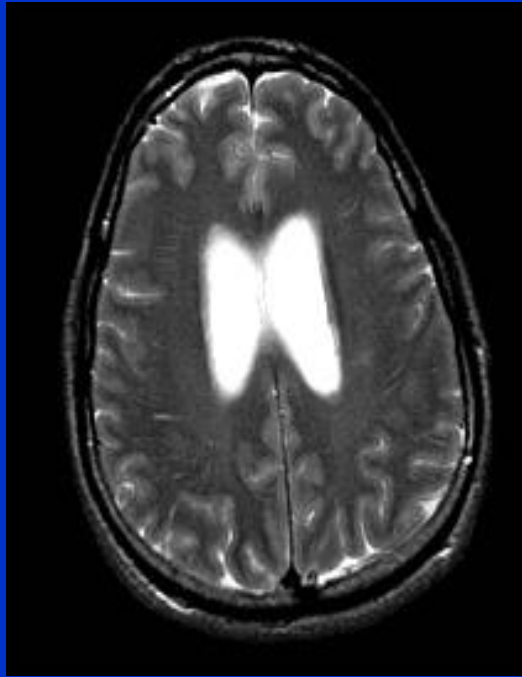
MRI: ASL

Functional Neuroimaging Techniques

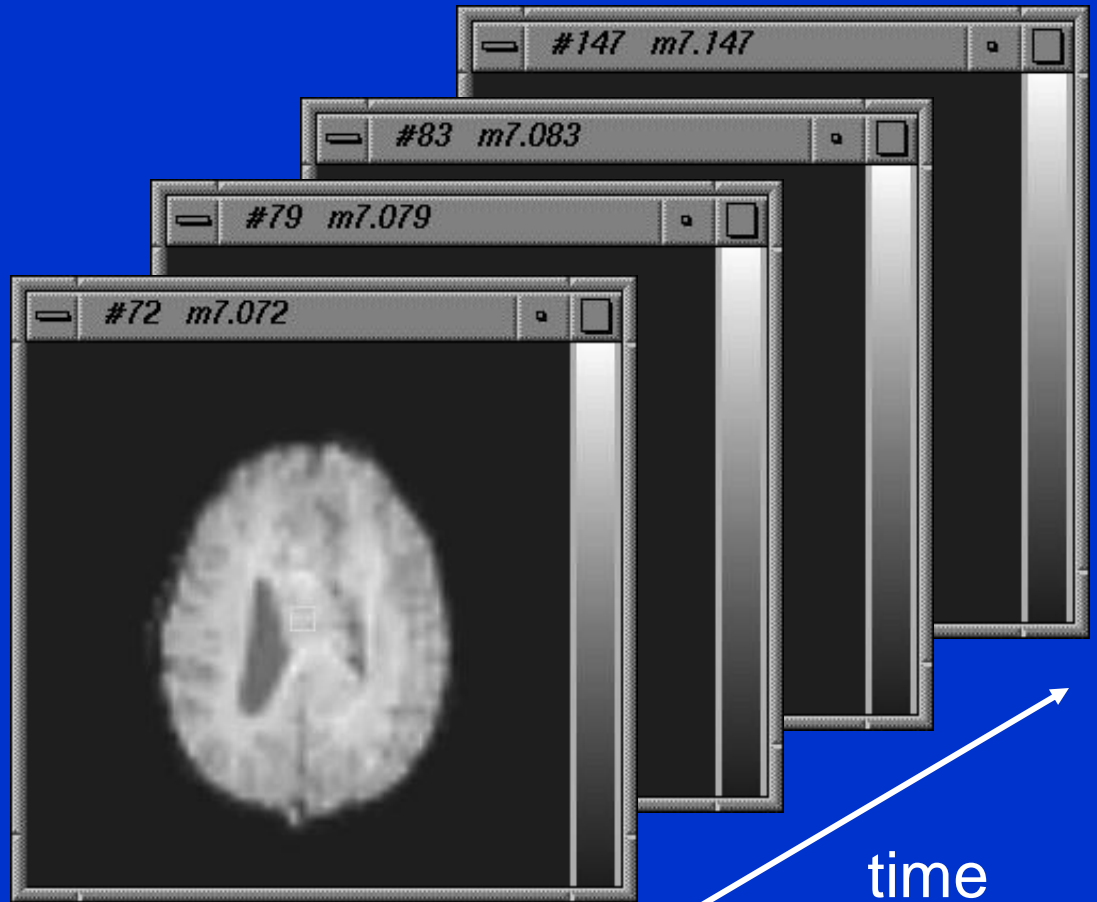


Contrast in Functional MRI

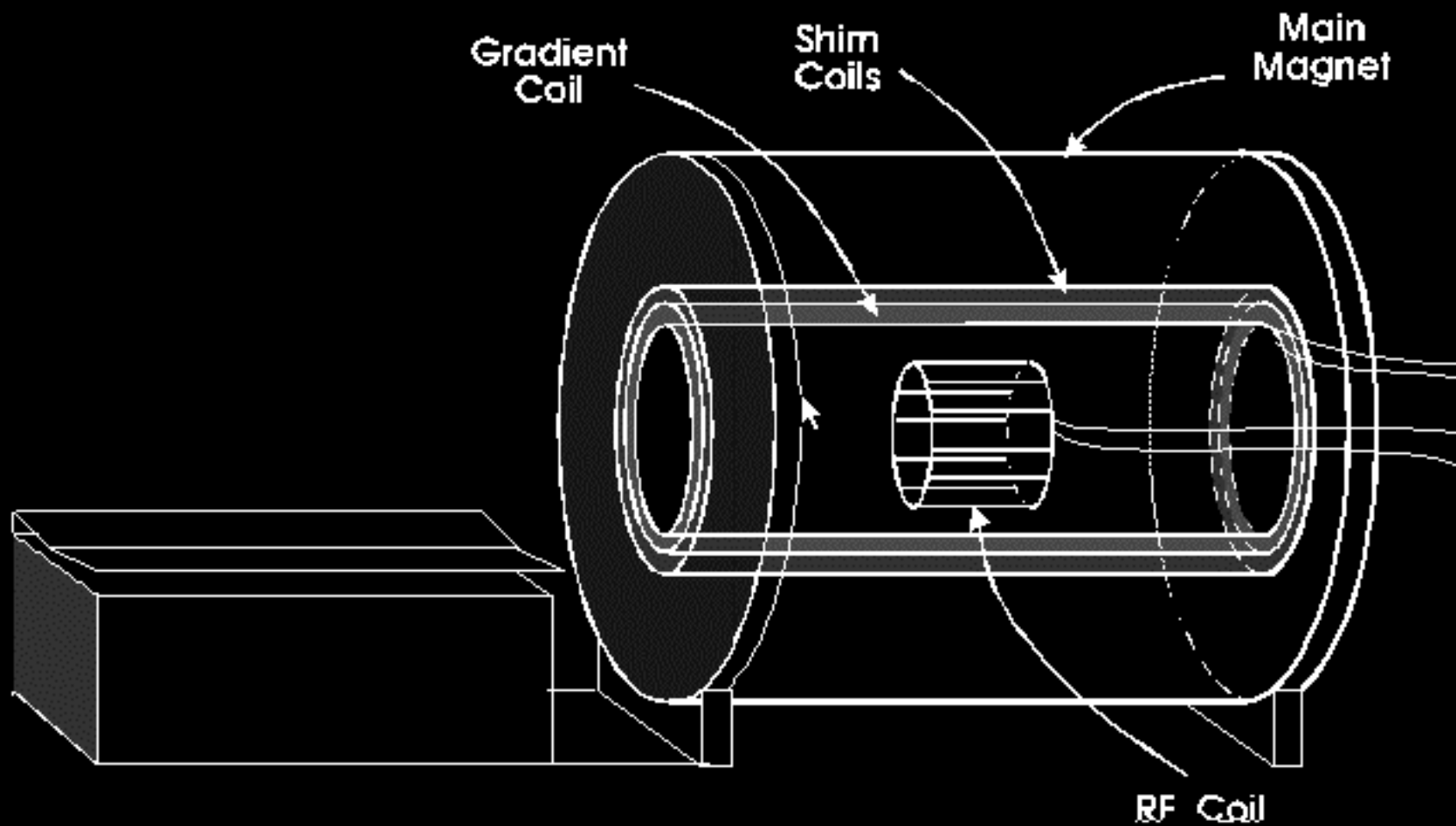
- **Blood Volume**
- **BOLD** (Blood Oxygenation Level Dependent Contrast)
- **Perfusion**
- **CMRO₂**



Anatomic



Functional



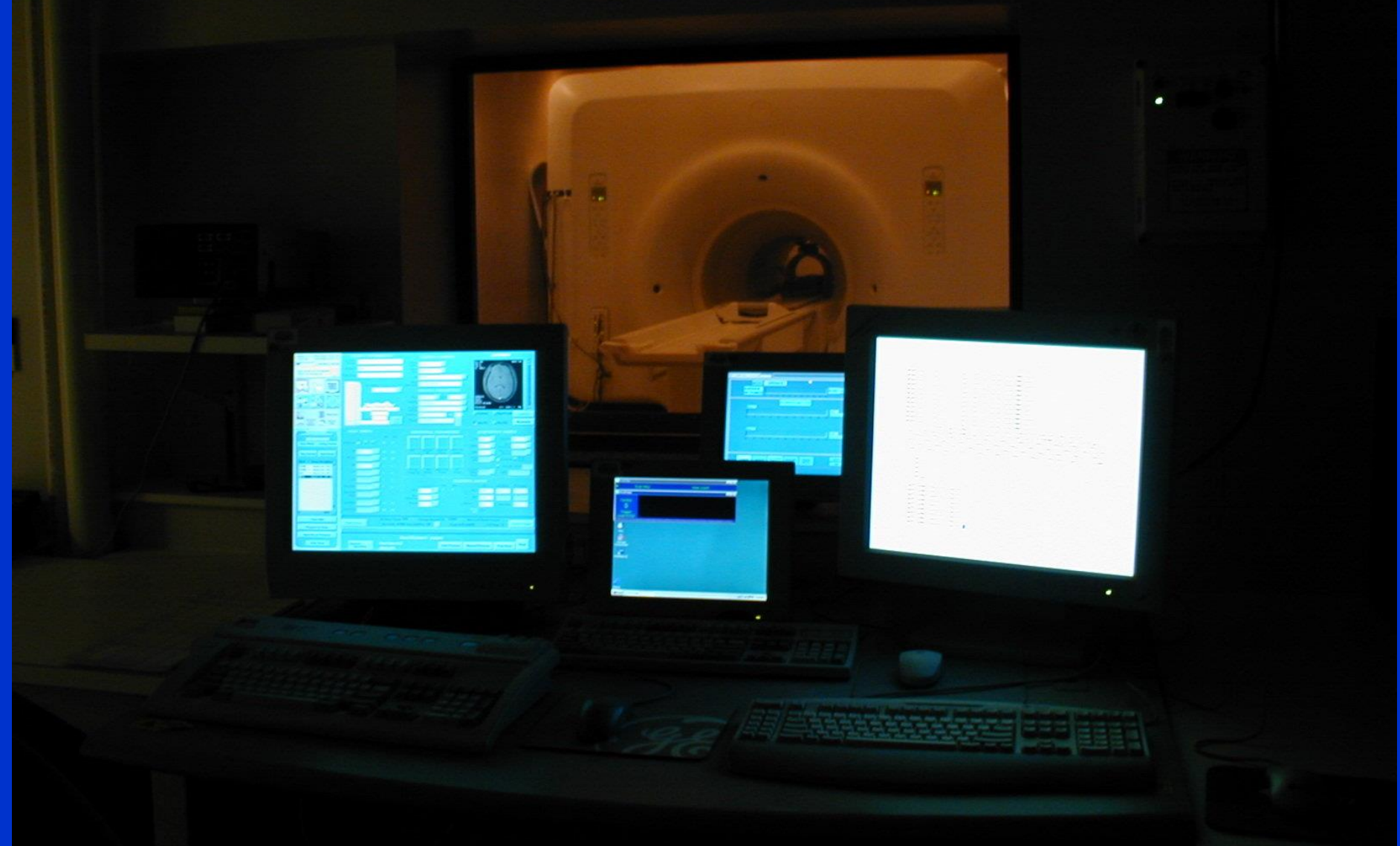1991-1992

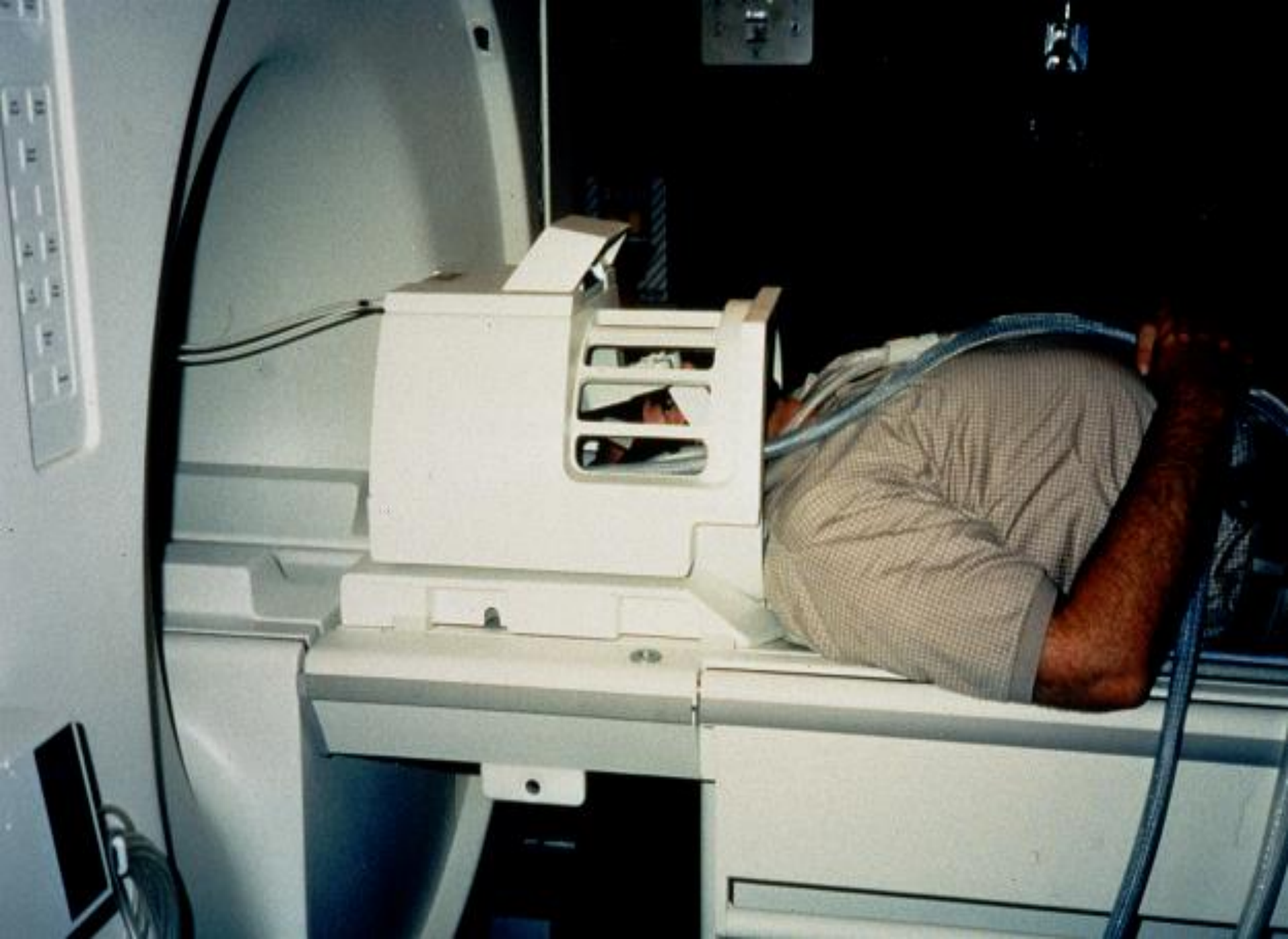

1992-1999



General Electric 3 Tesla Scanner





MRI Instrumentation

Computer
Graphics



VCR



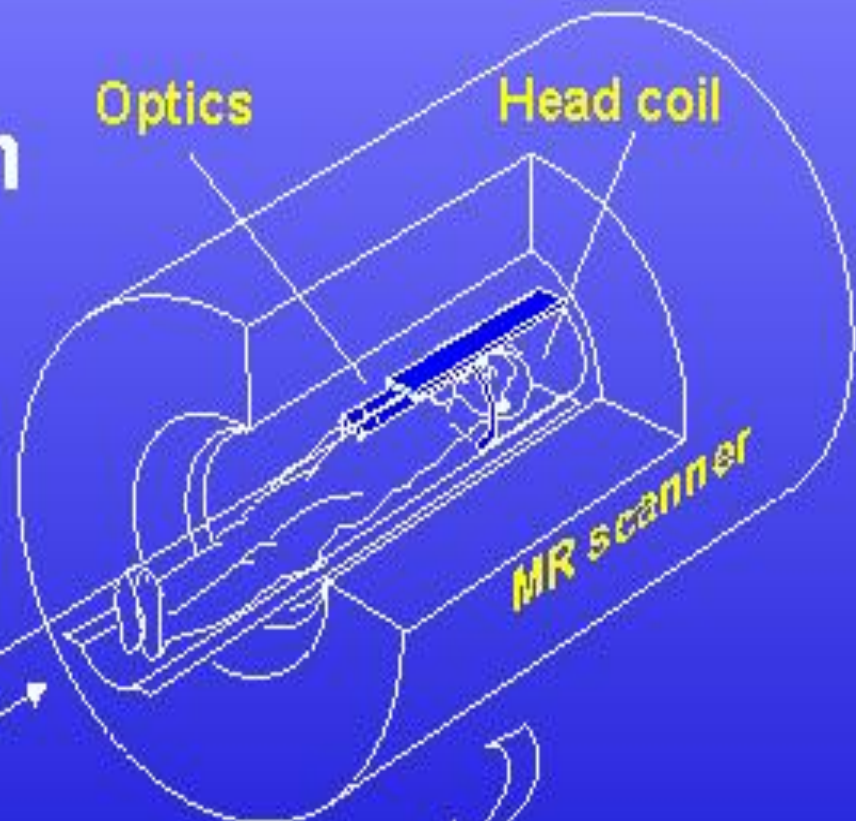
Video Image
Source



16"

Optics

Head coil



MR scanner



Baseline Task



Experimental Task

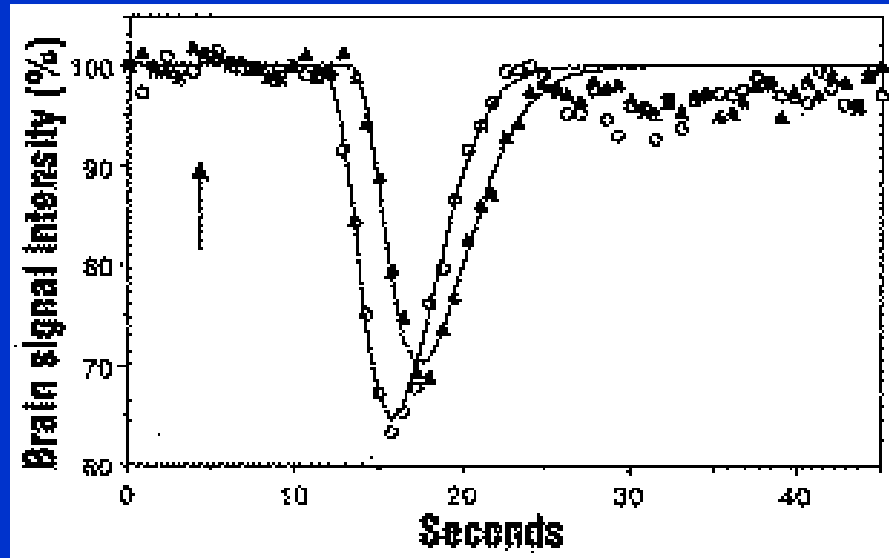
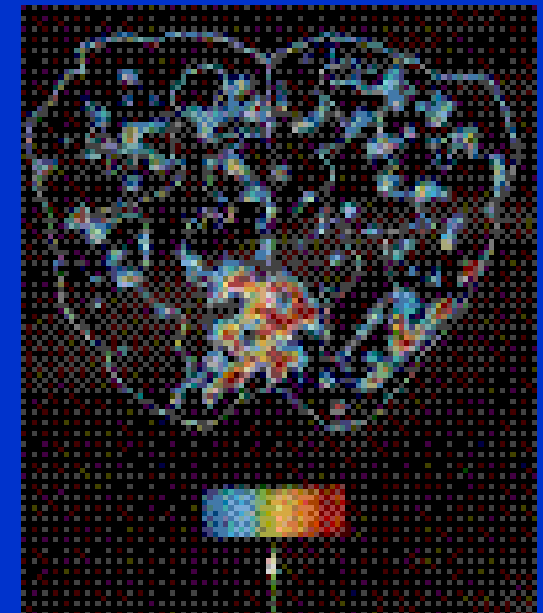





Blood Volume Changes with Brain Activation

Resting

Active

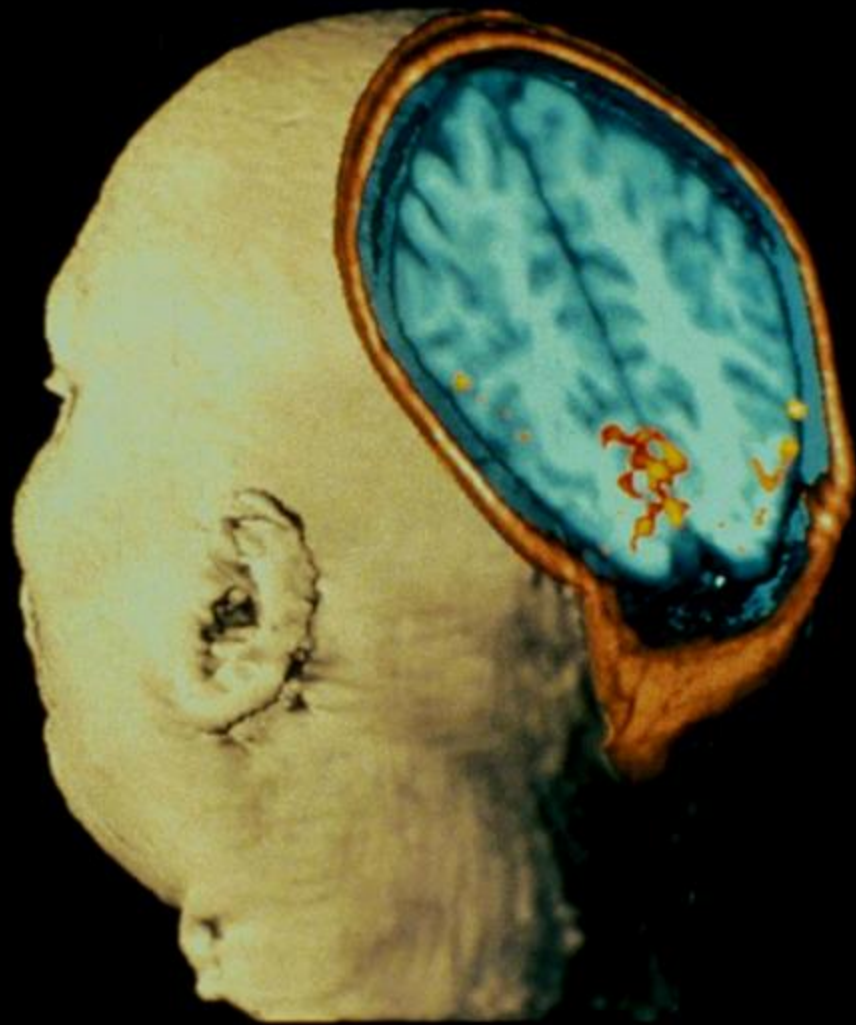


Photic Stimulation

MRI Image showing
activation of the
Visual Cortex

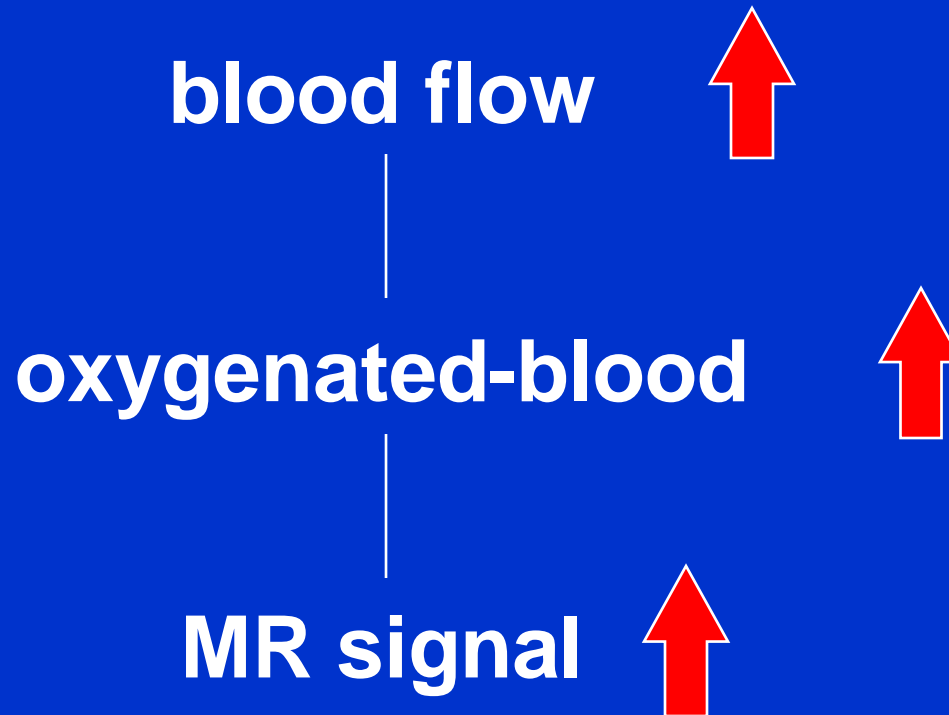
From Belliveau, et al.
Science Nov 1991

MSC - perfusion

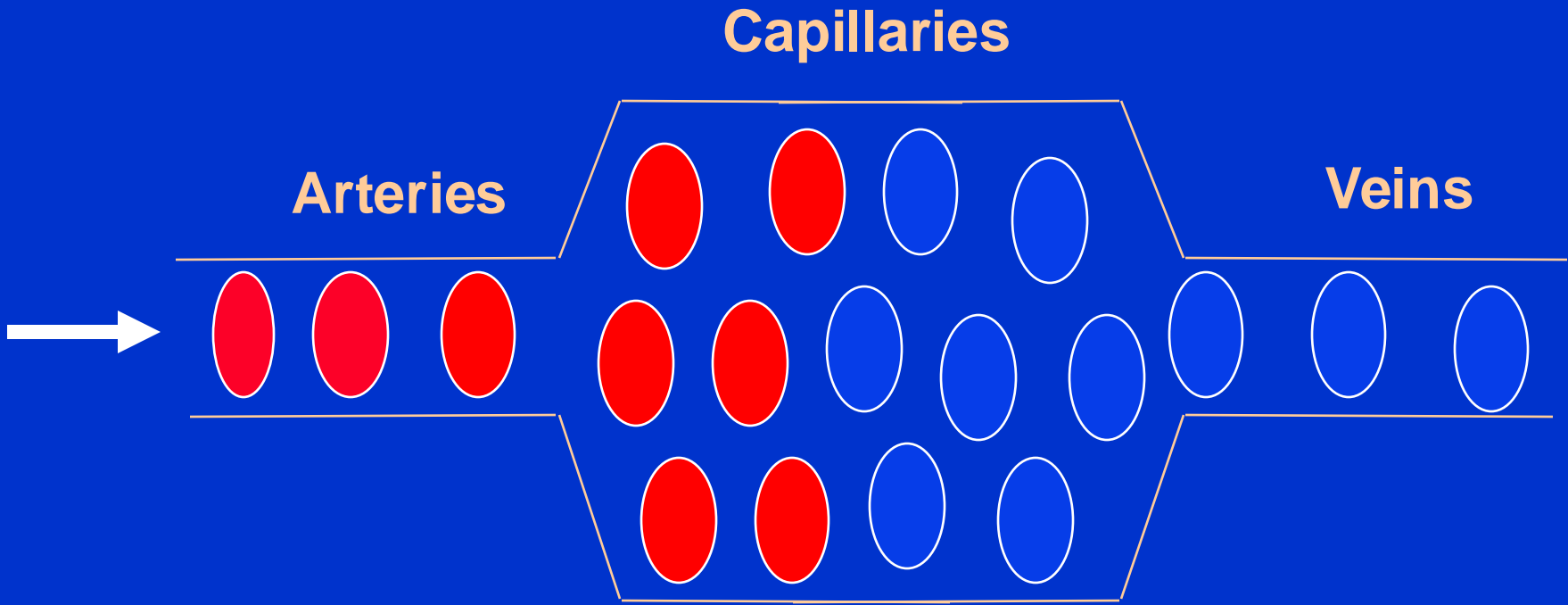


BOLD

(blood oxygenation level dependence)

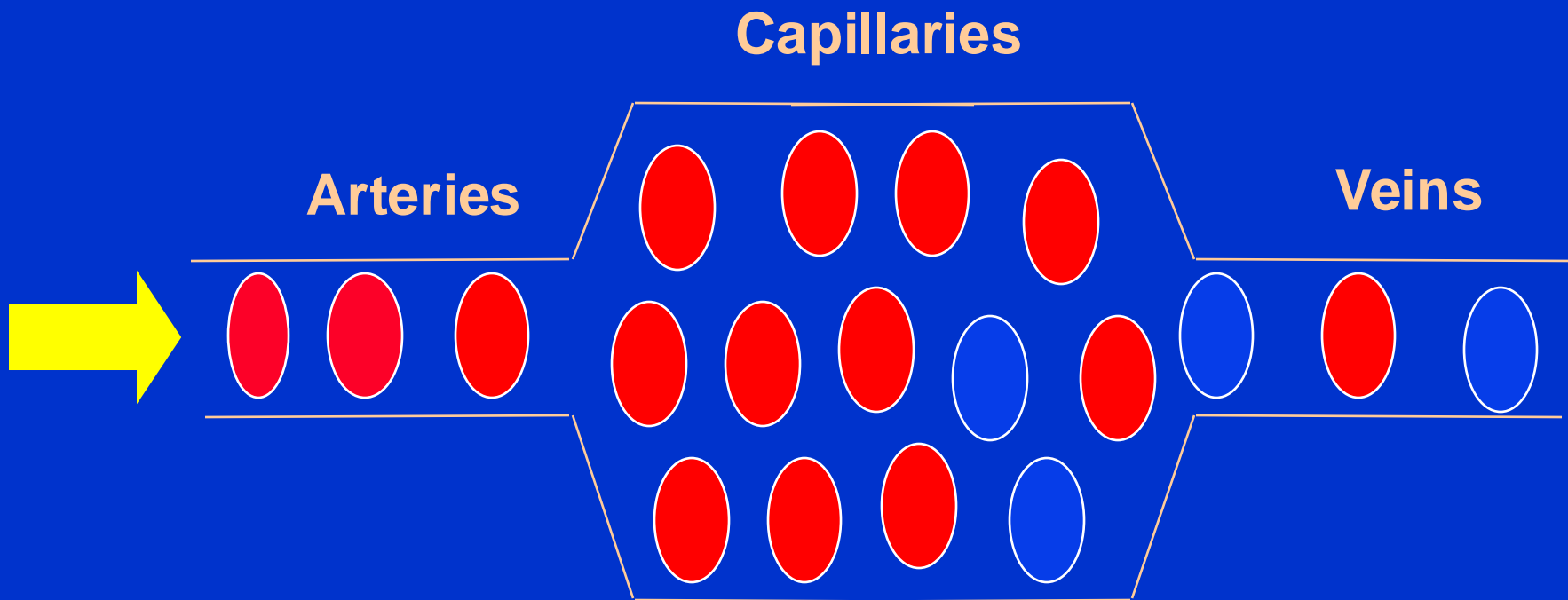


BOLD: Resting Perfusion



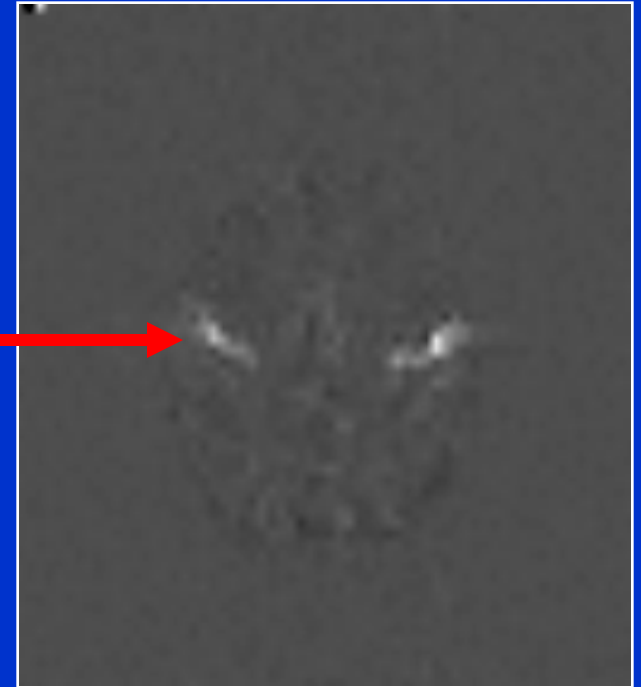
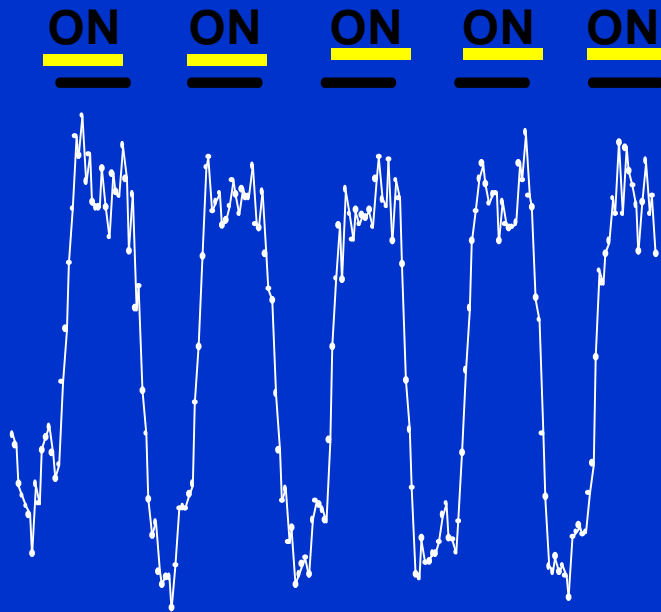
SIGNAL

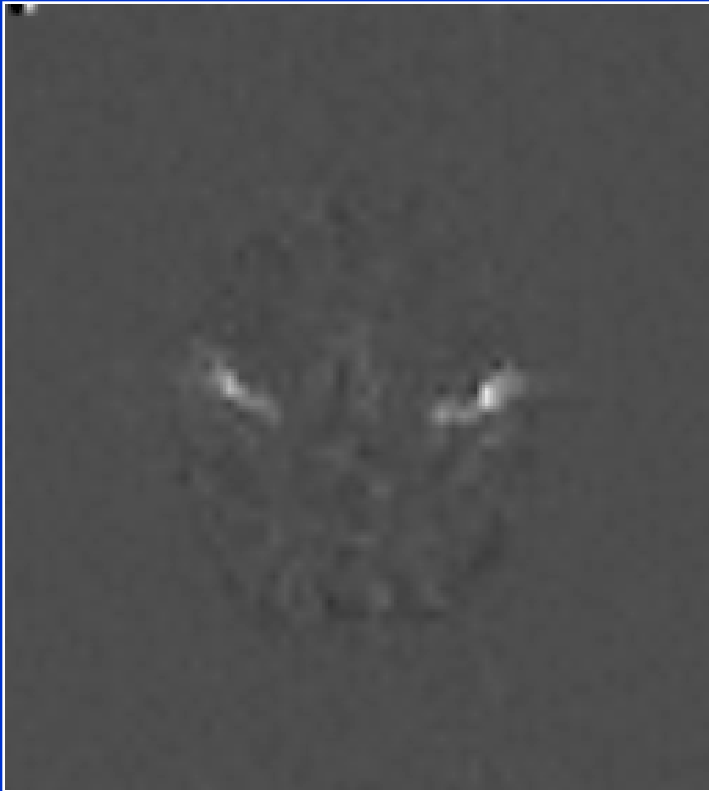BOLD: **Activated** Perfusion



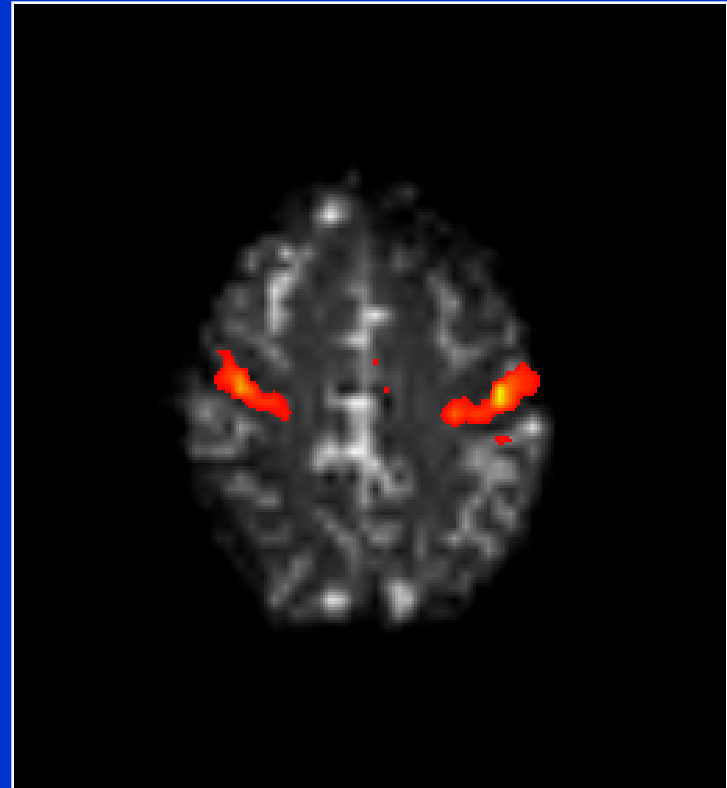
SIGNAL

BOLD: Motor Cortex Activation





Cross Correlation Image

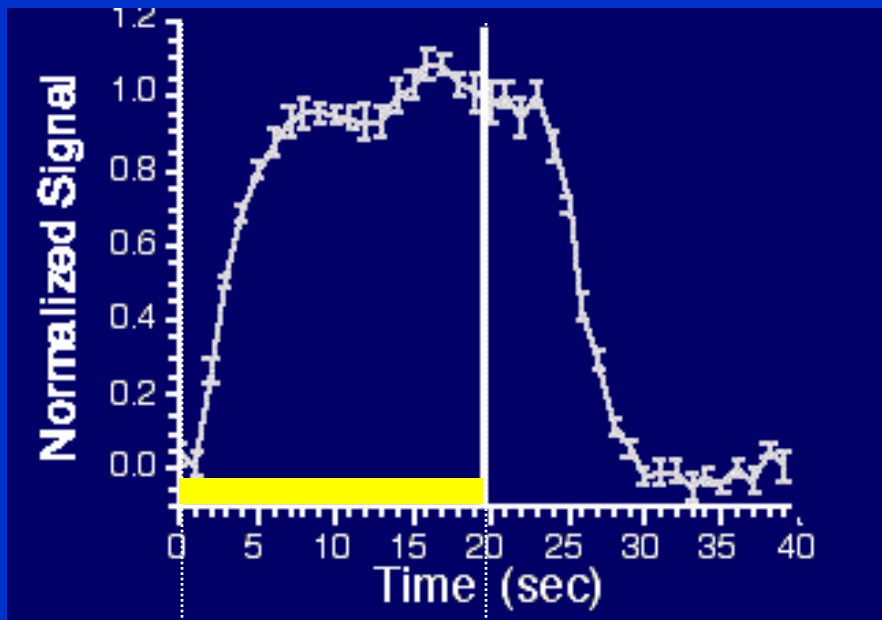


Cross Correlation Image
Anatomical Image

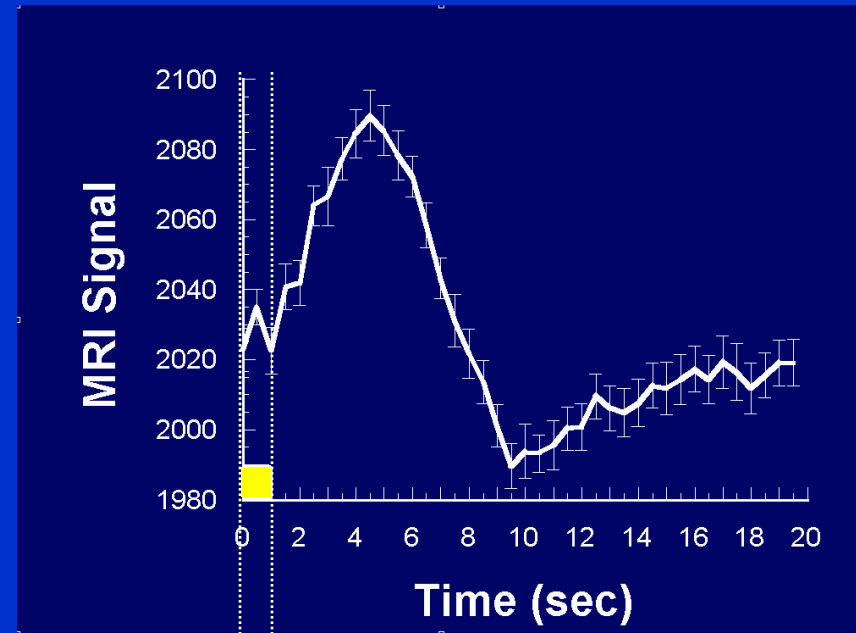


The BOLD Signal

Blood Oxygenation Level Dependent (BOLD) signal changes



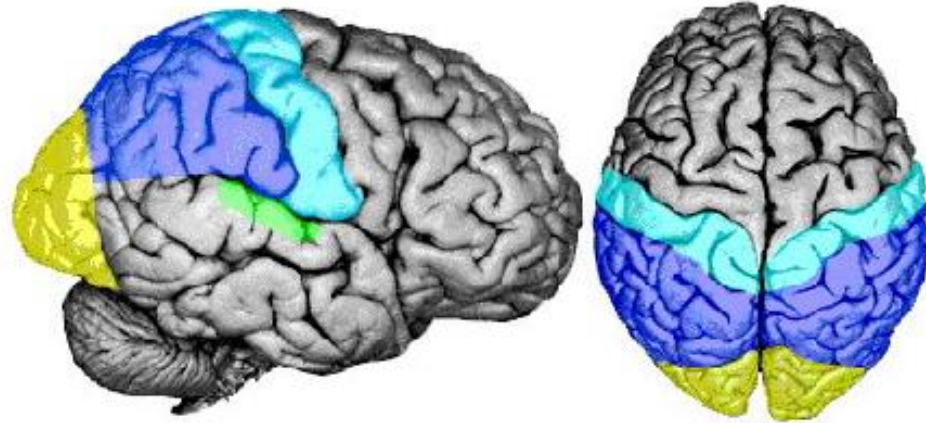
task



task

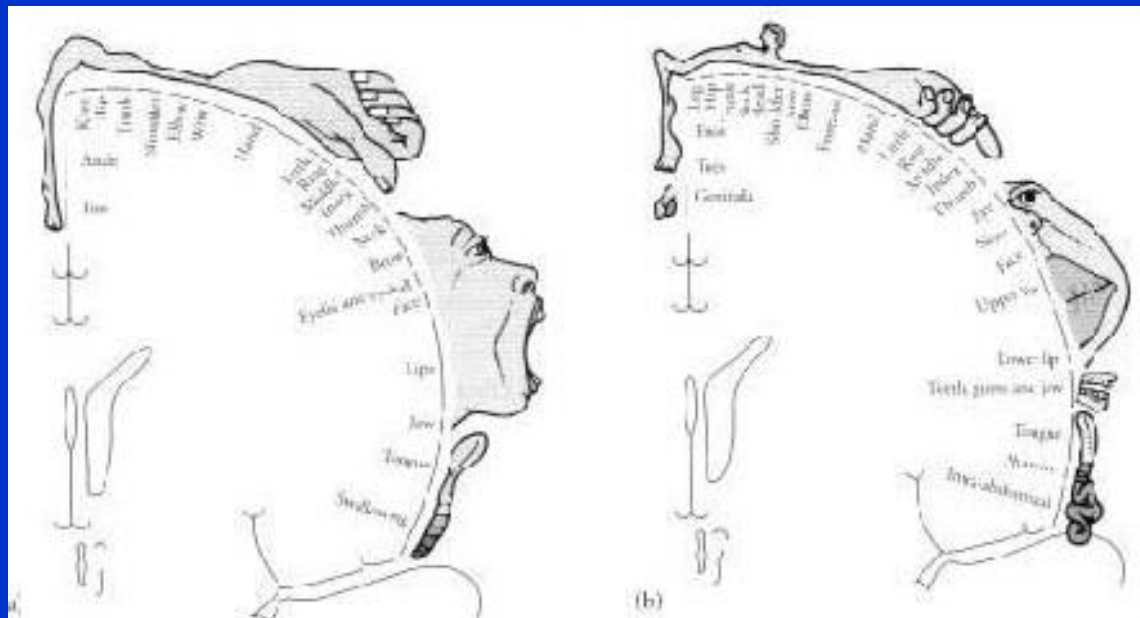
Alternating Left and Right Finger Tapping





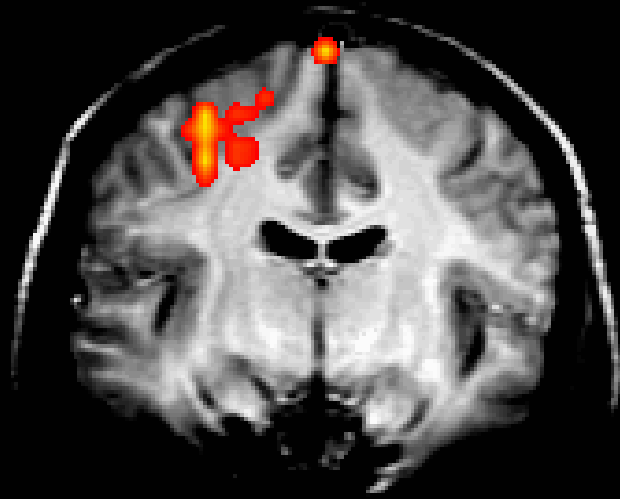■ Parietal/
Somatosensory
■ Parietal/
Association Area

■ Occipital/Vision
■ Auditory

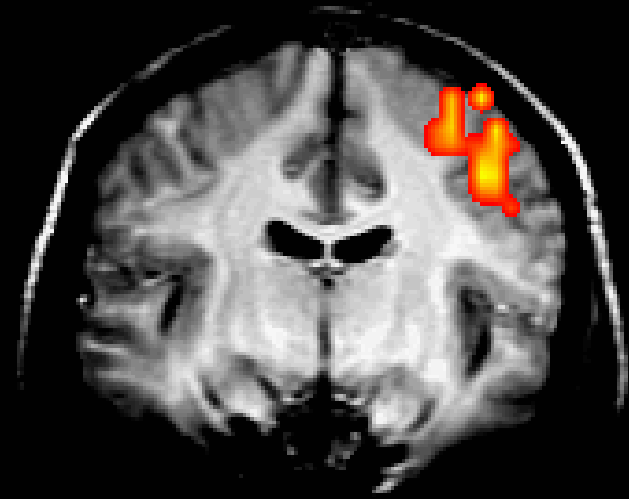


Finger Movement

Left

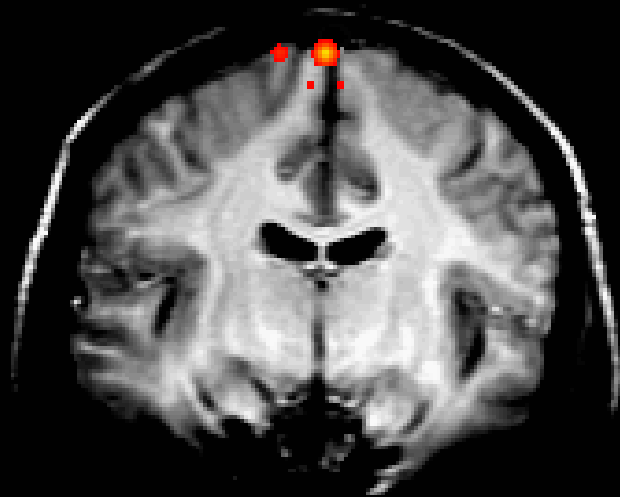


Right

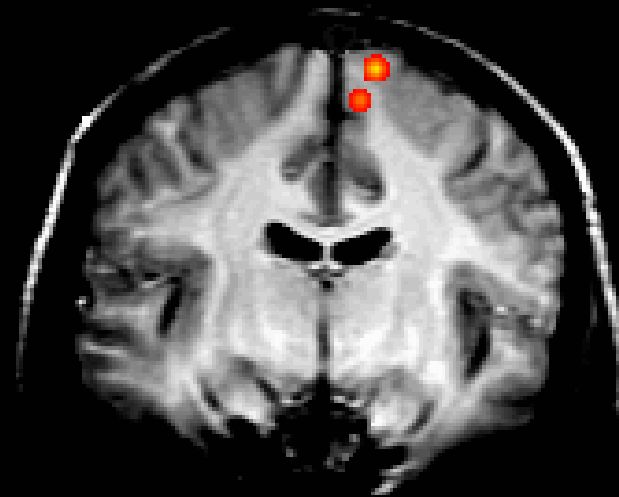


Toe Movement

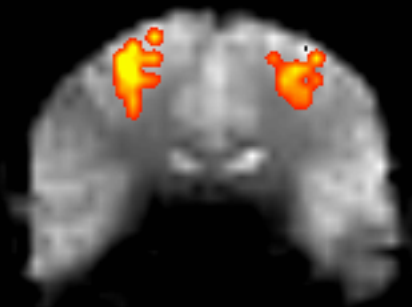Left



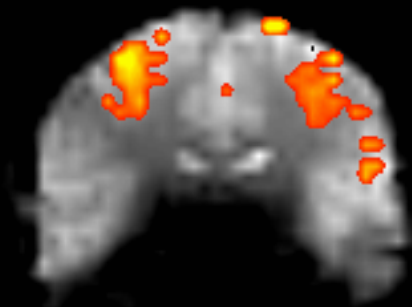
Right



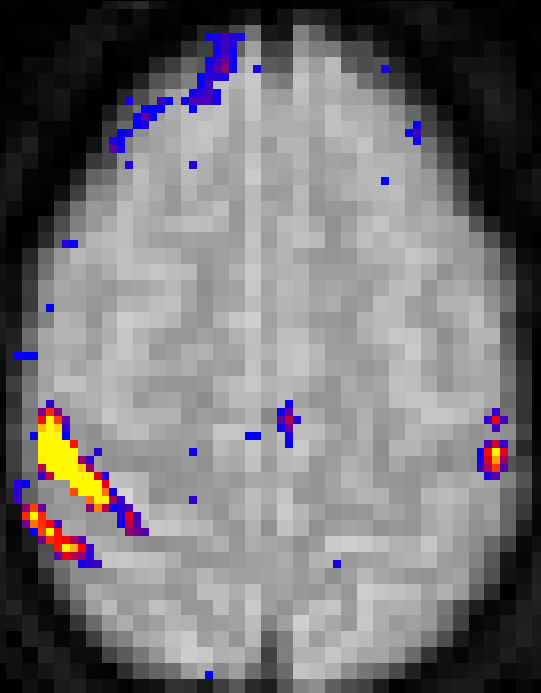
Wrist



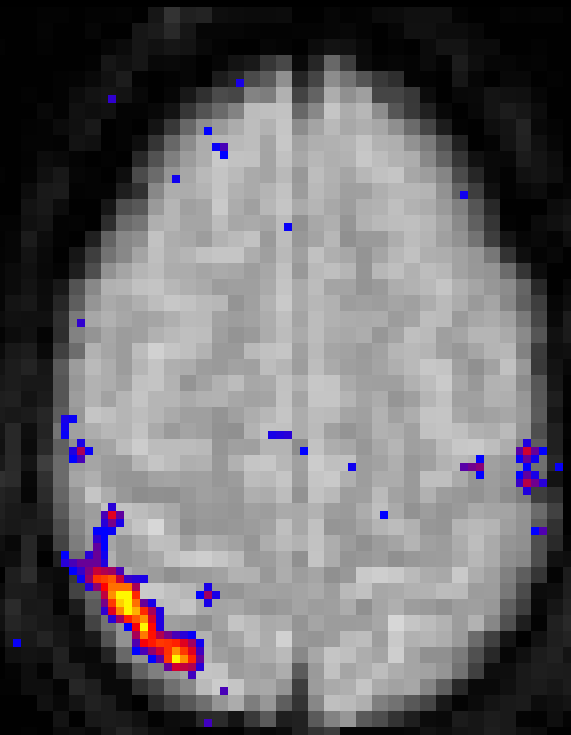
Fingers



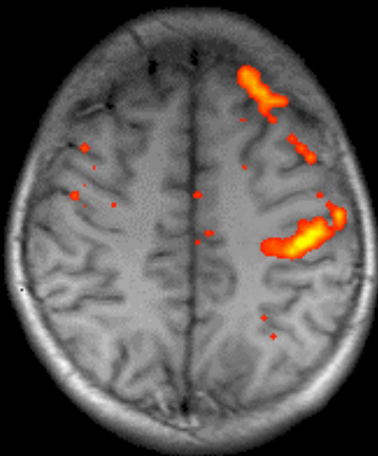
Finger Movement



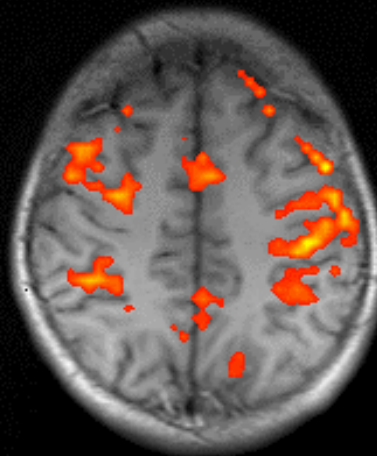
Tactile Stimulation



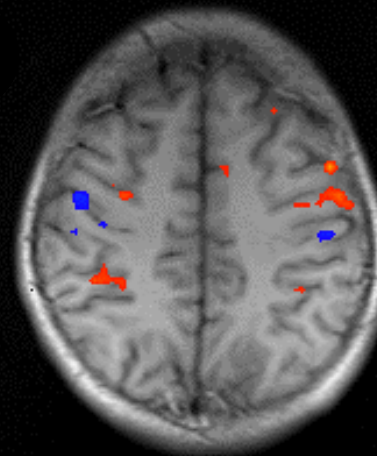
Simple Right



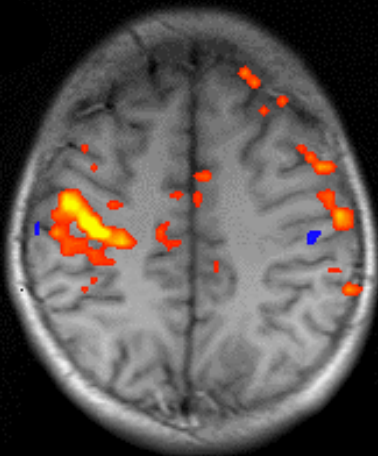
Complex Right



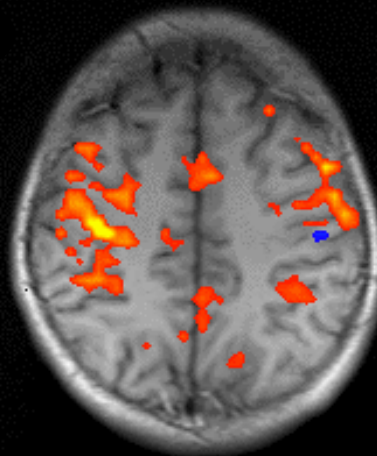
Imagined Complex Right



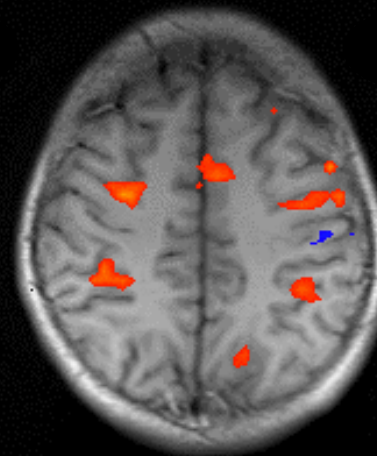
Simple Left



Complex Left

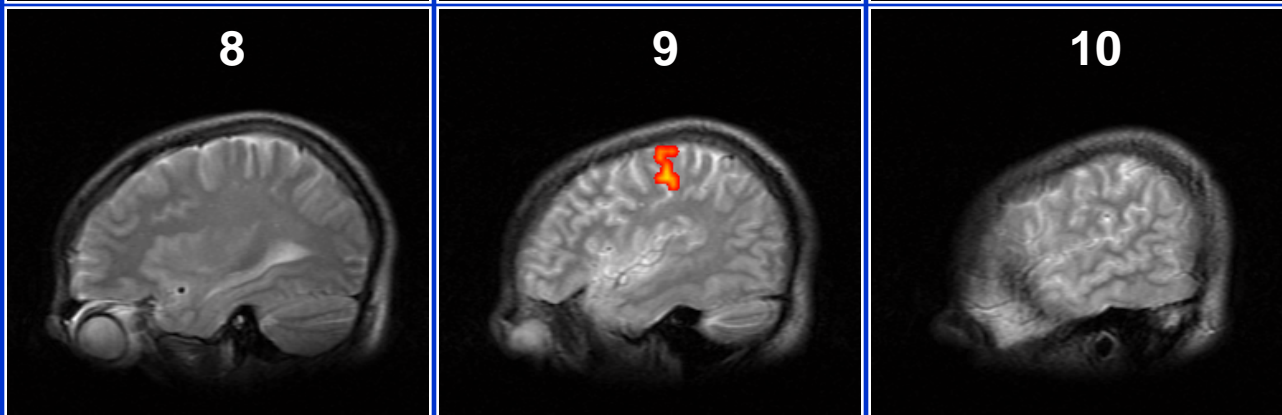
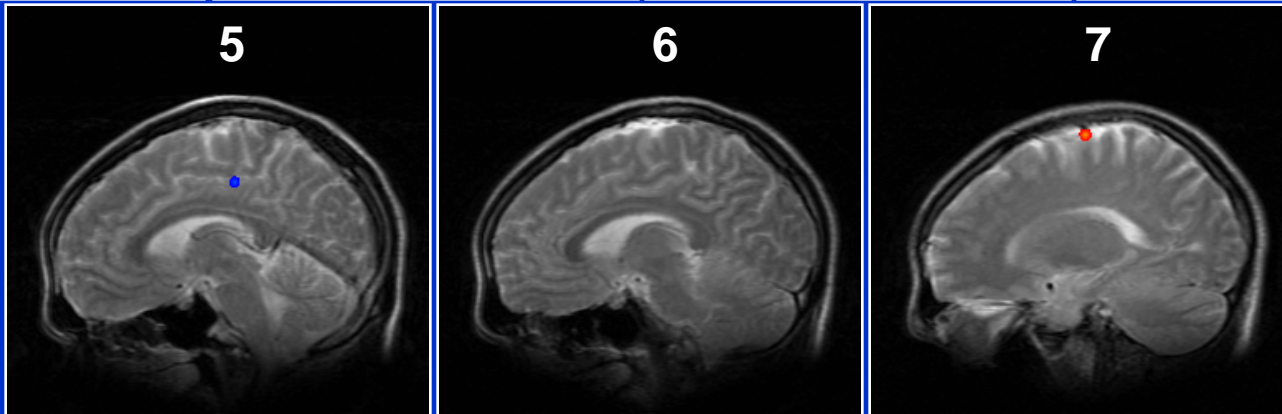
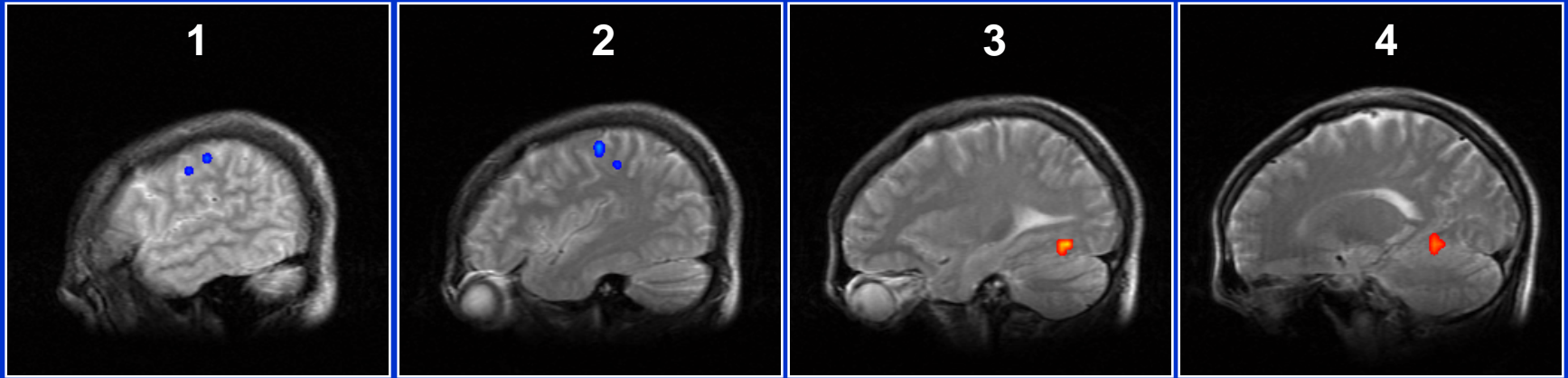


Imagined Complex Left



Left

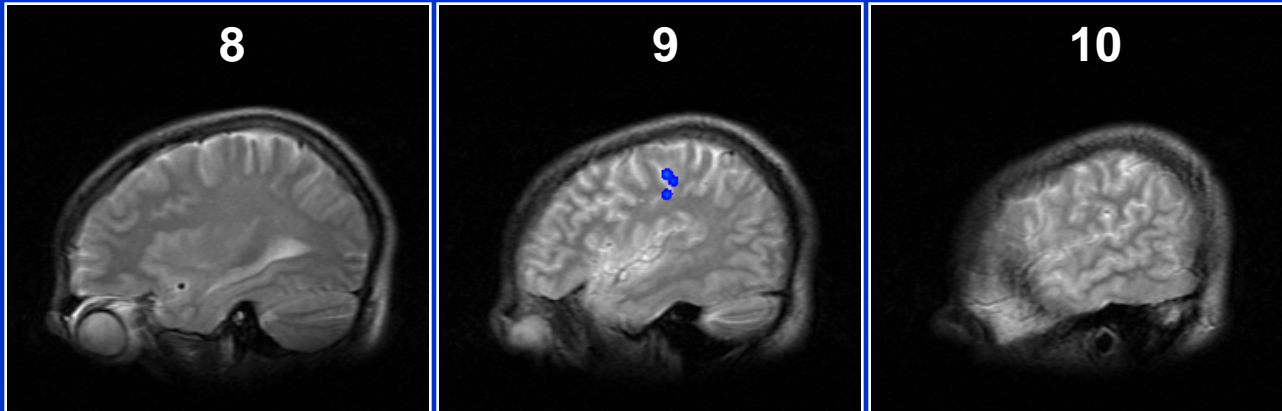
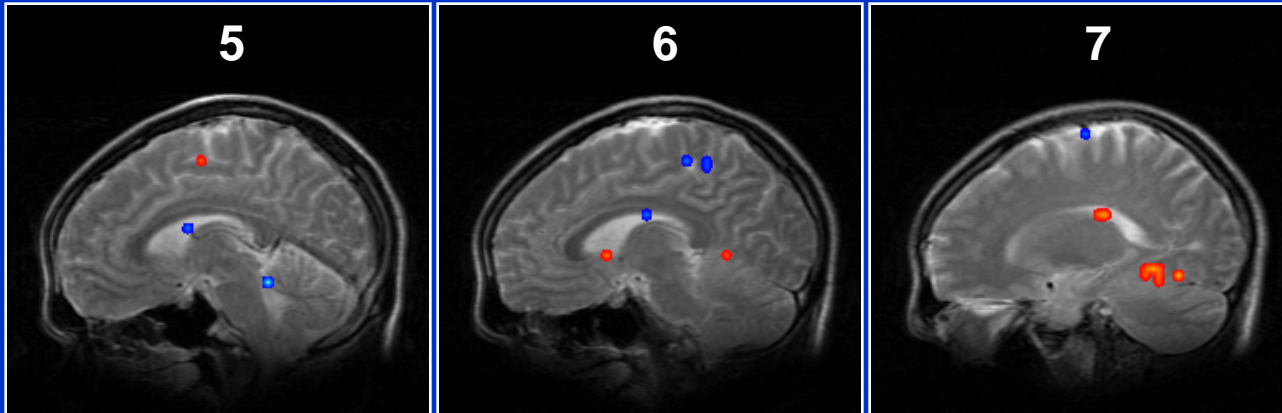
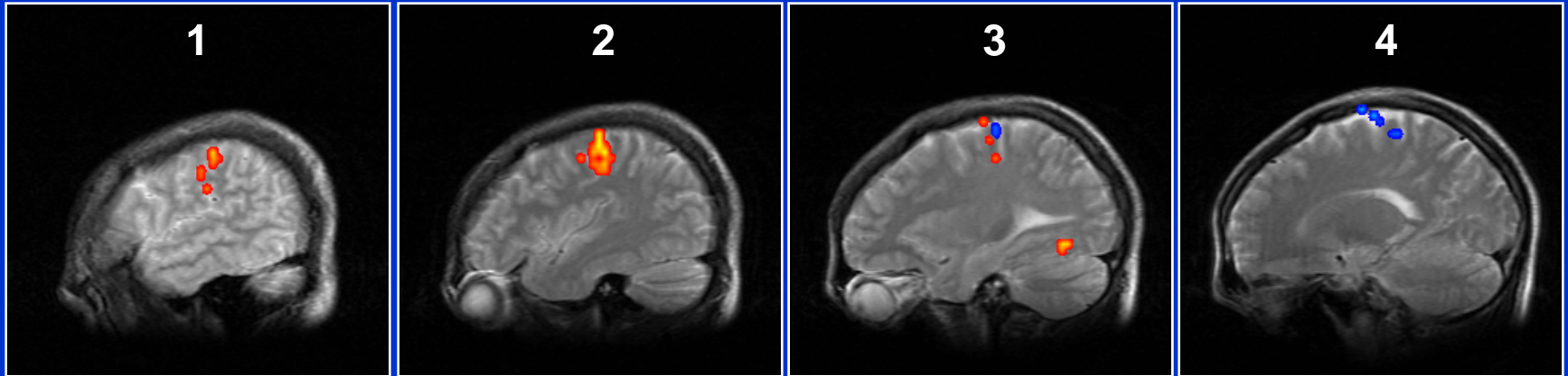
Simple Finger Movement on the Left Hand



Right

Left

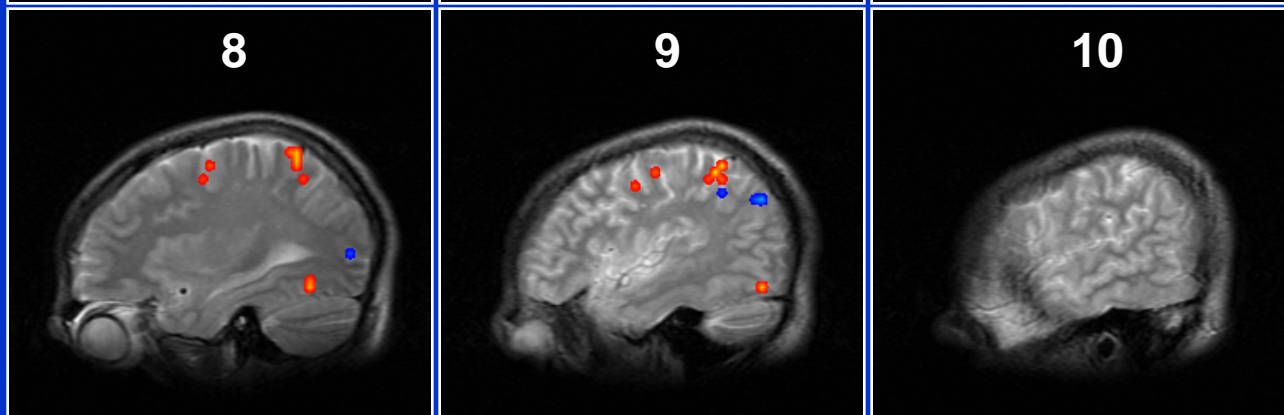
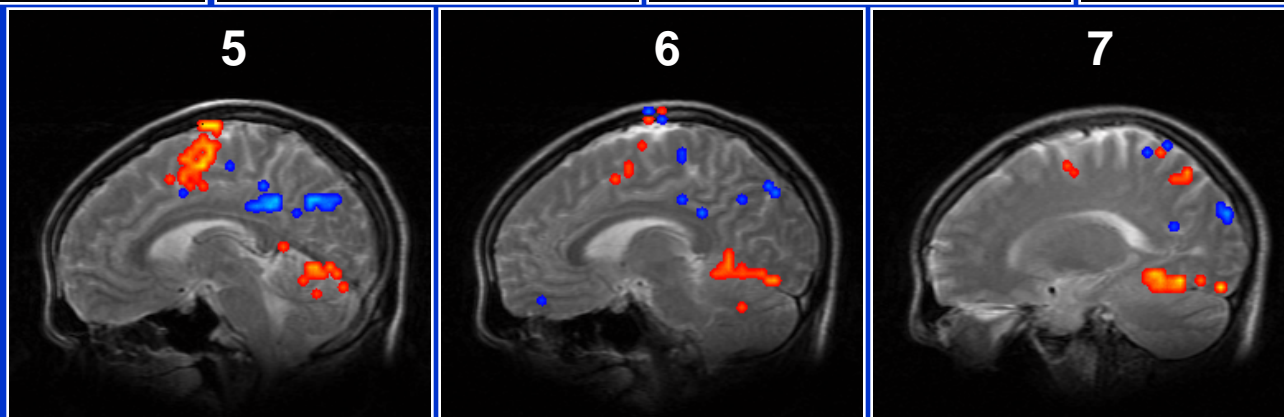
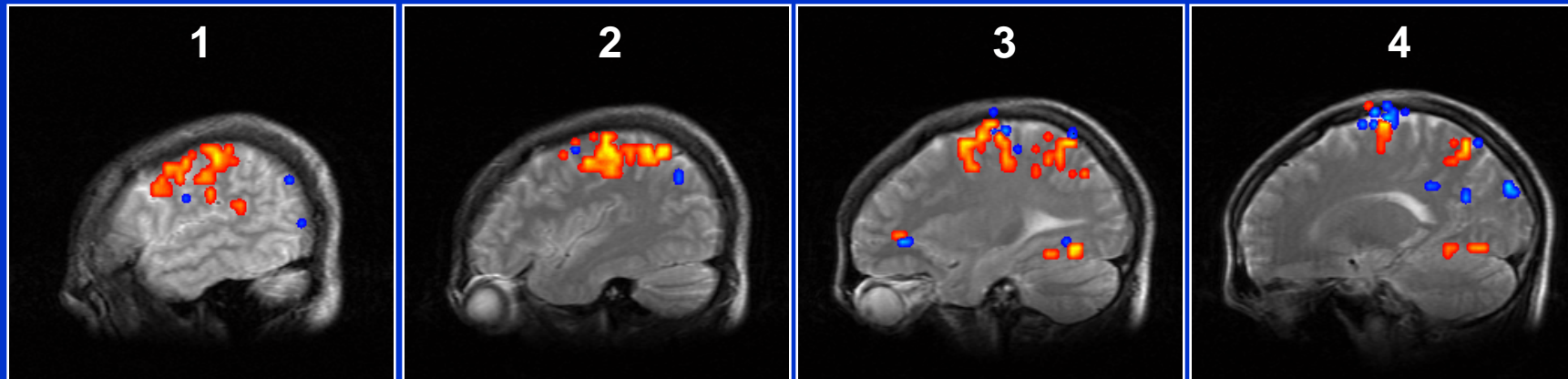
Simple Finger Movement on the Right Hand



Right

Left

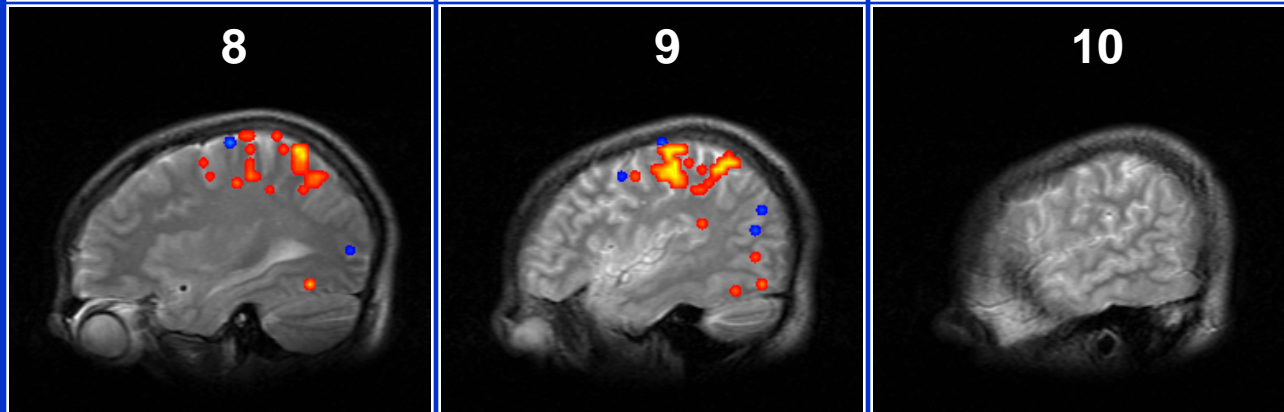
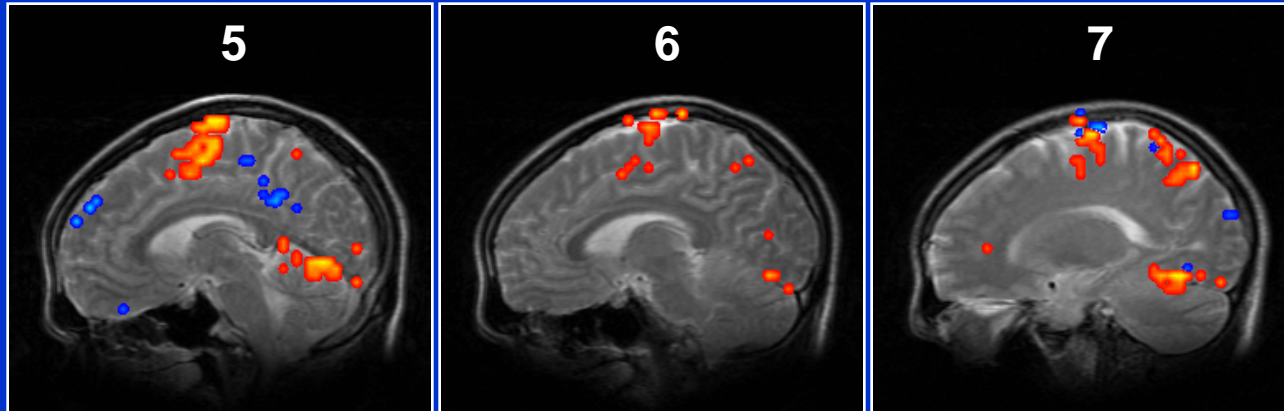
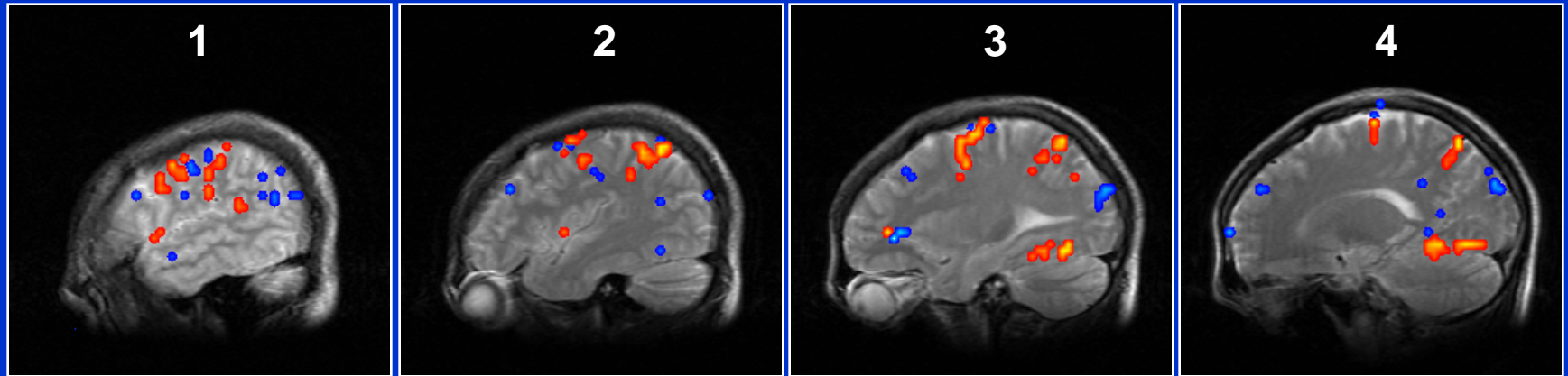
Complex Finger Movement on the Right Hand



Right

Left

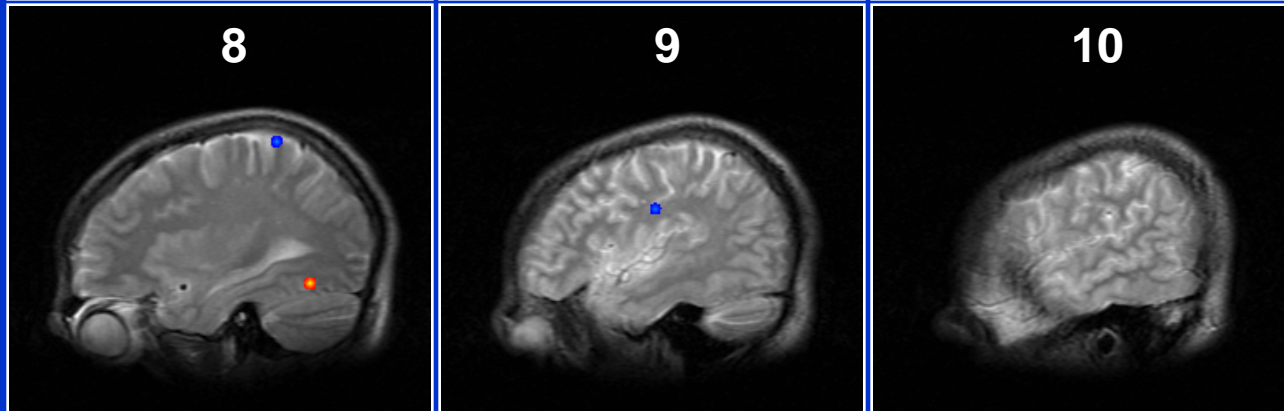
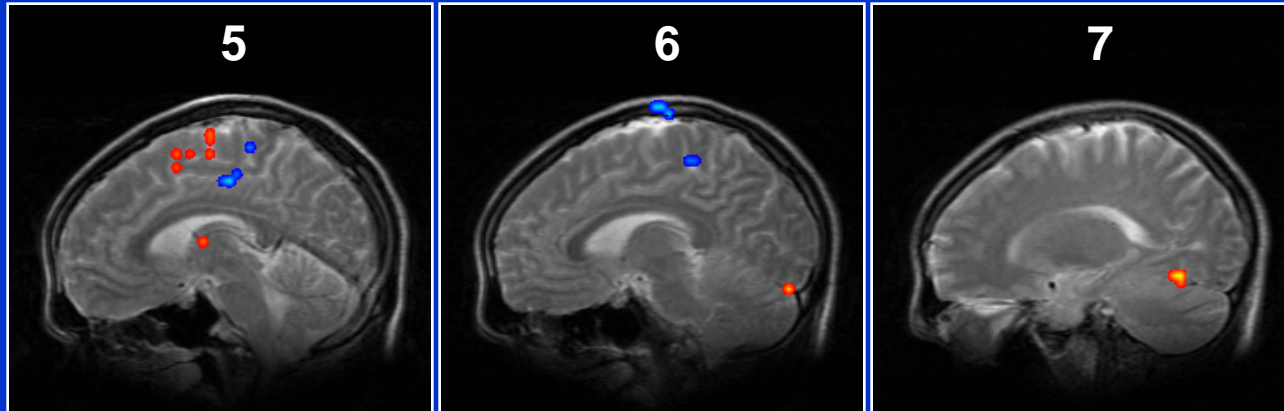
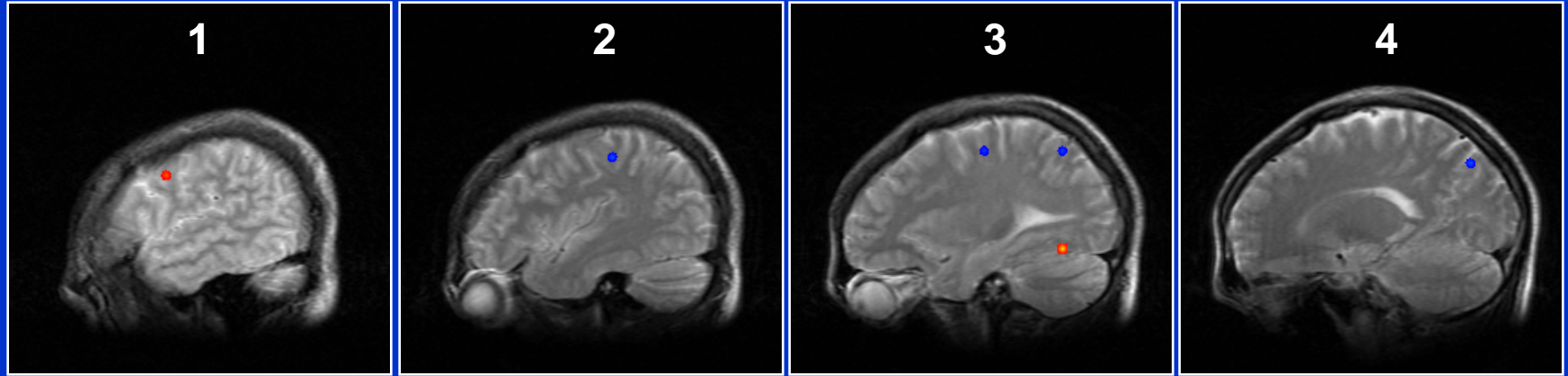
Complex Finger Movement on the Left Hand



Right

Left

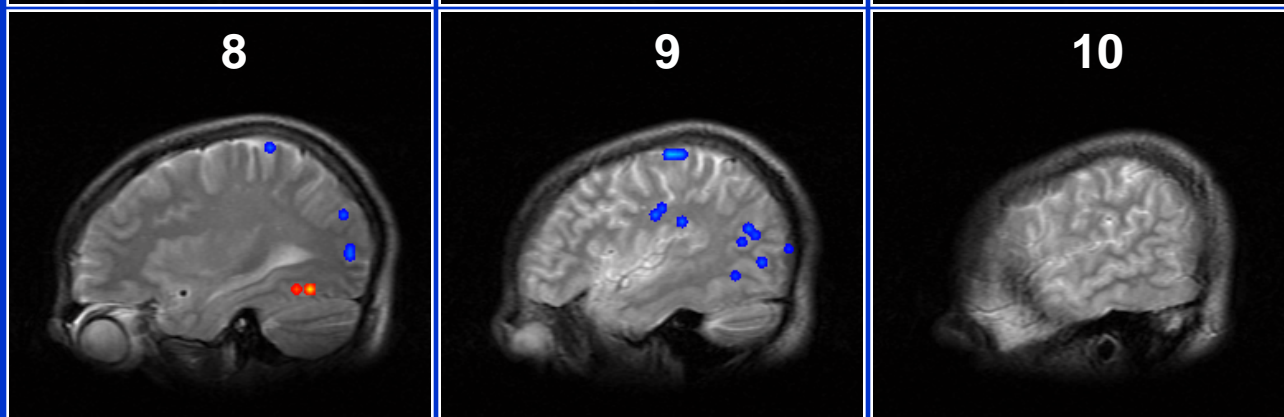
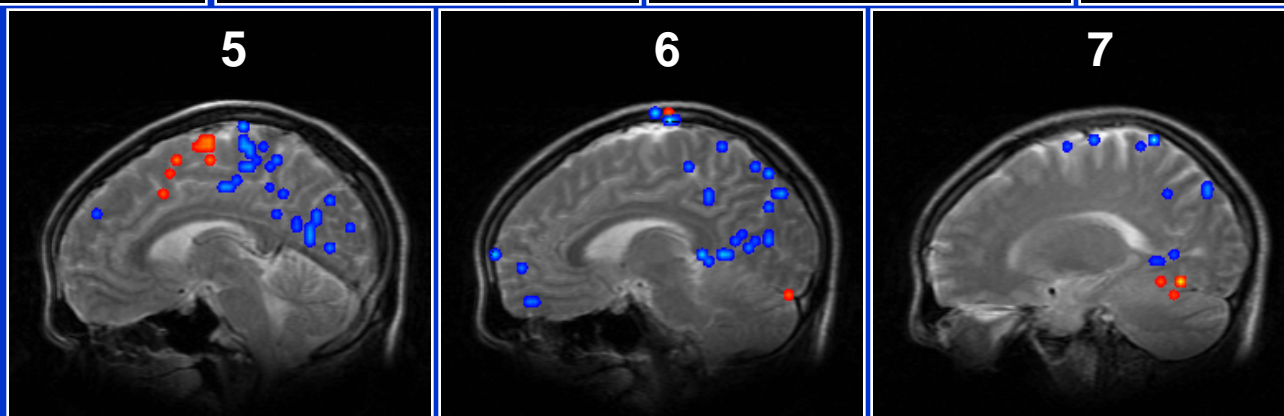
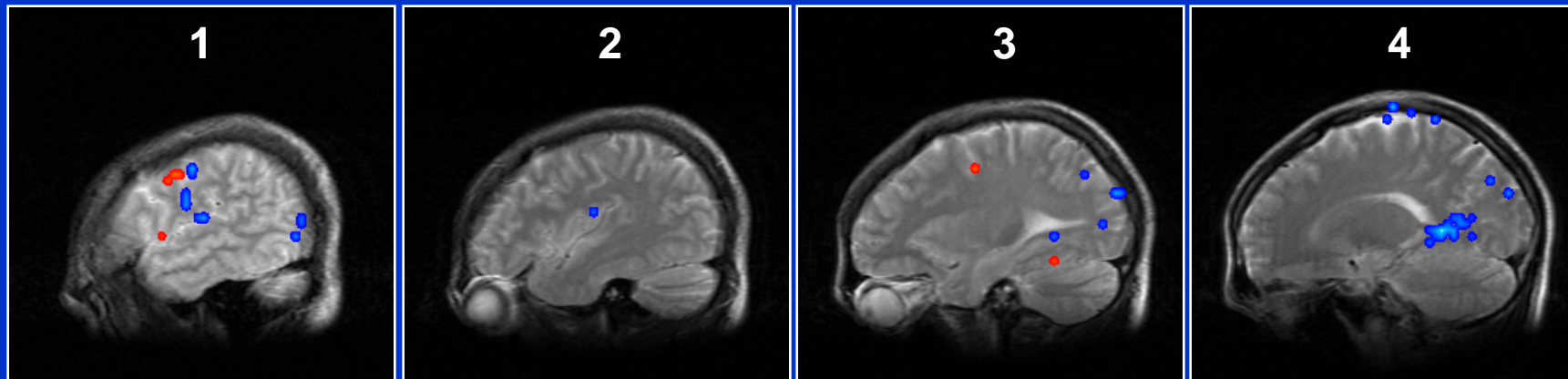
Imagined Complex Finger Movement on the Left Hand



Right

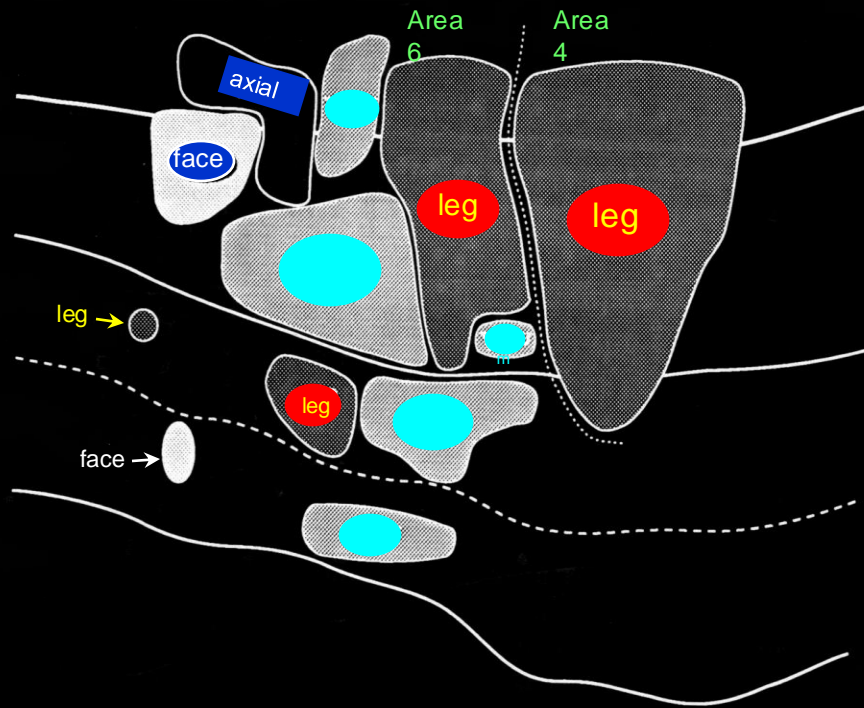
Left

Imagined Complex Finger Movement on the Right Hand

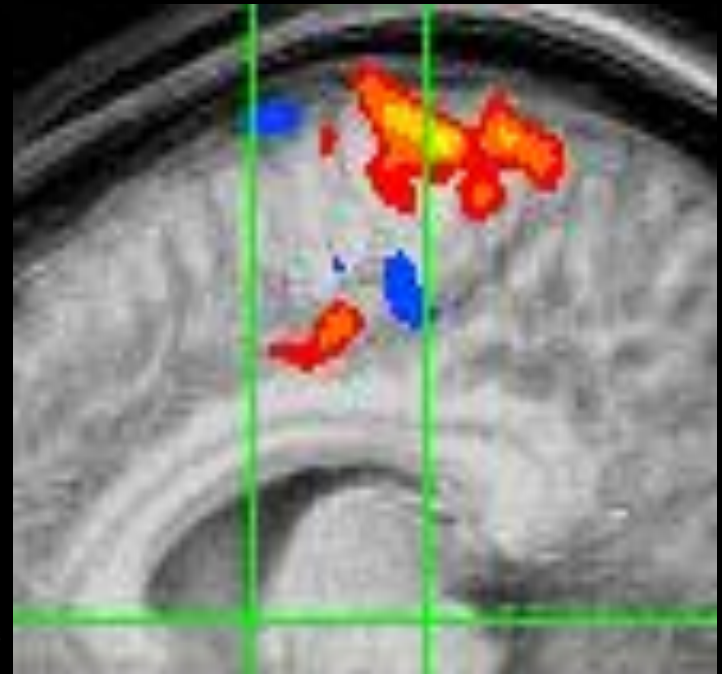


Right

FMRI of Leg Motor Topography - Medial Wall

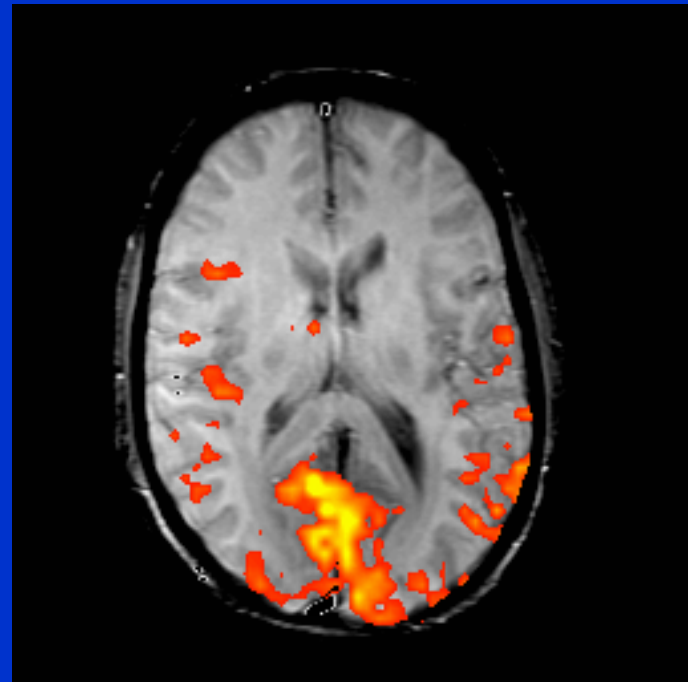
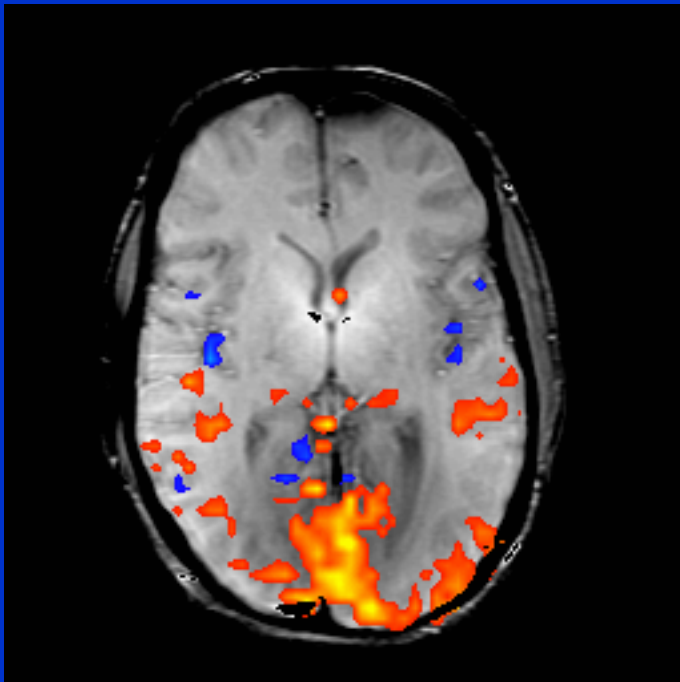


Macaque

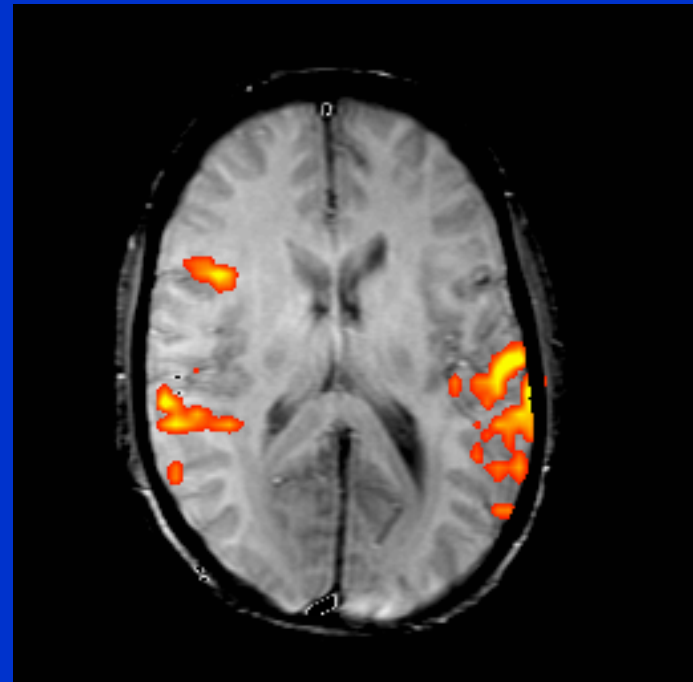
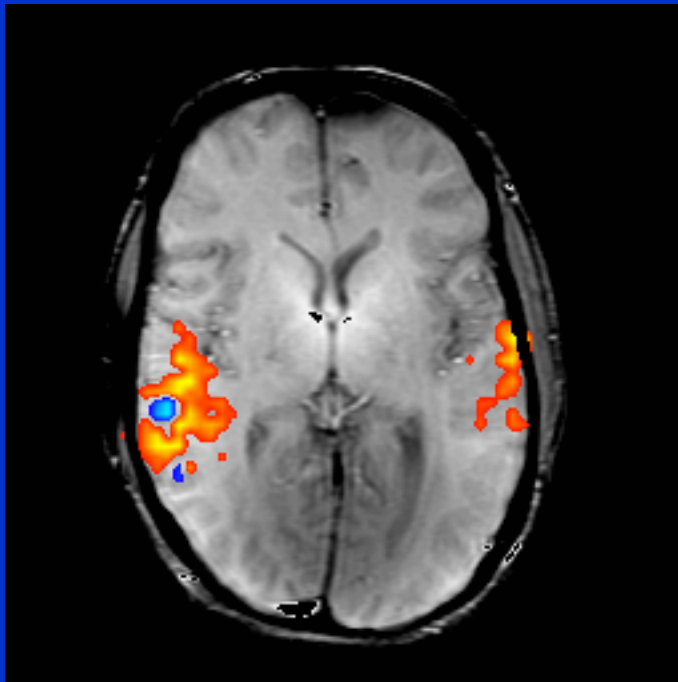


Human

Reading

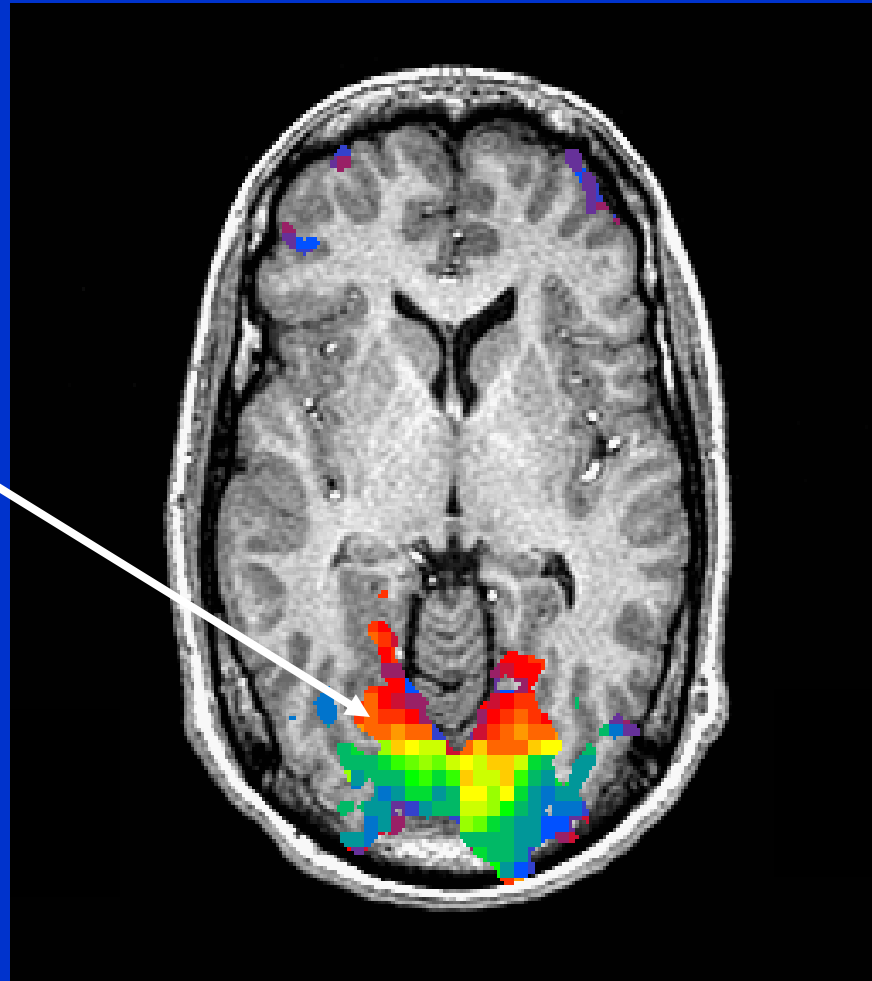


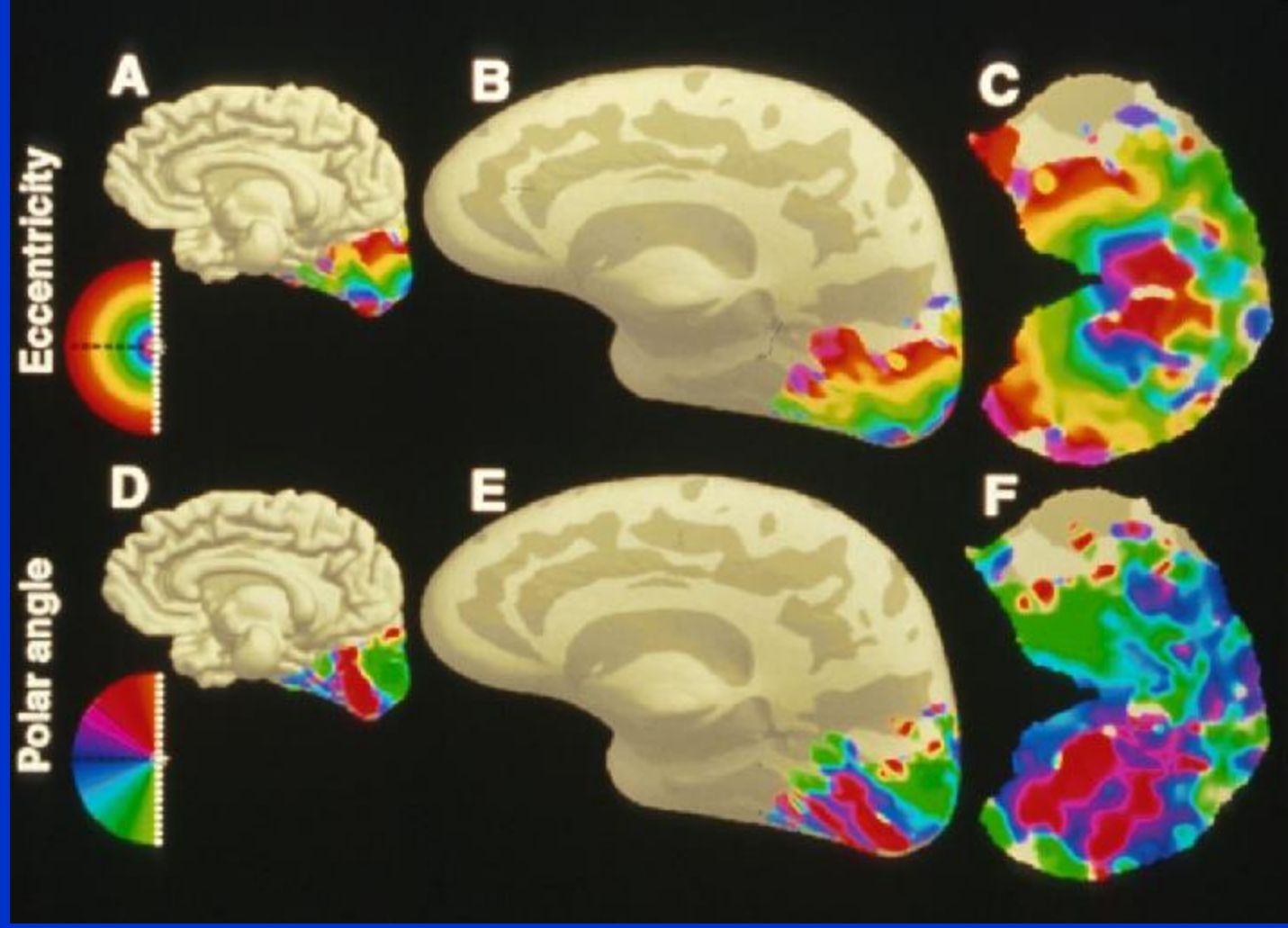
Listening to Spoken Words



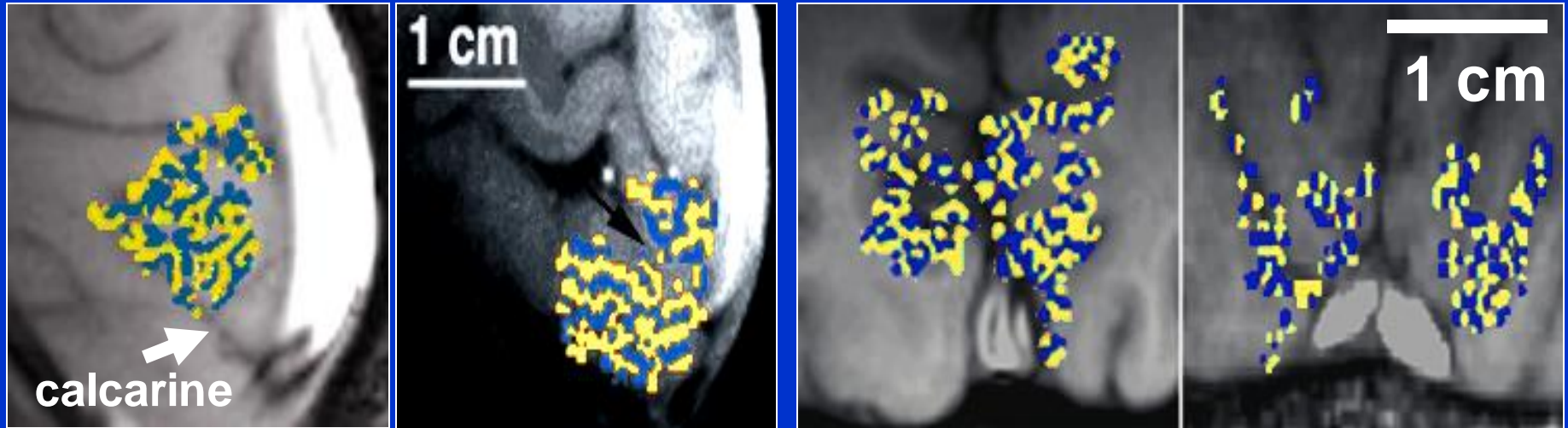
fMRI Mapping of Visual Cortex

Functional
Activation
(Color codes
visual field
eccentricity)





ODC Maps using fMRI



- Identical in size, orientation, and appearance to those obtained by optical imaging¹ and histology^{3,4}.

Menon et al.

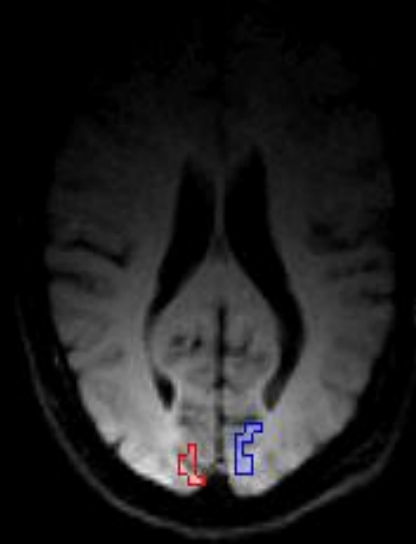
¹Malonek D, Grinvald A. *Science* 272, 551-4 (1996).

³Horton JC, Hocking DR. *J Neurosci* 16, 7228-39 (1996).

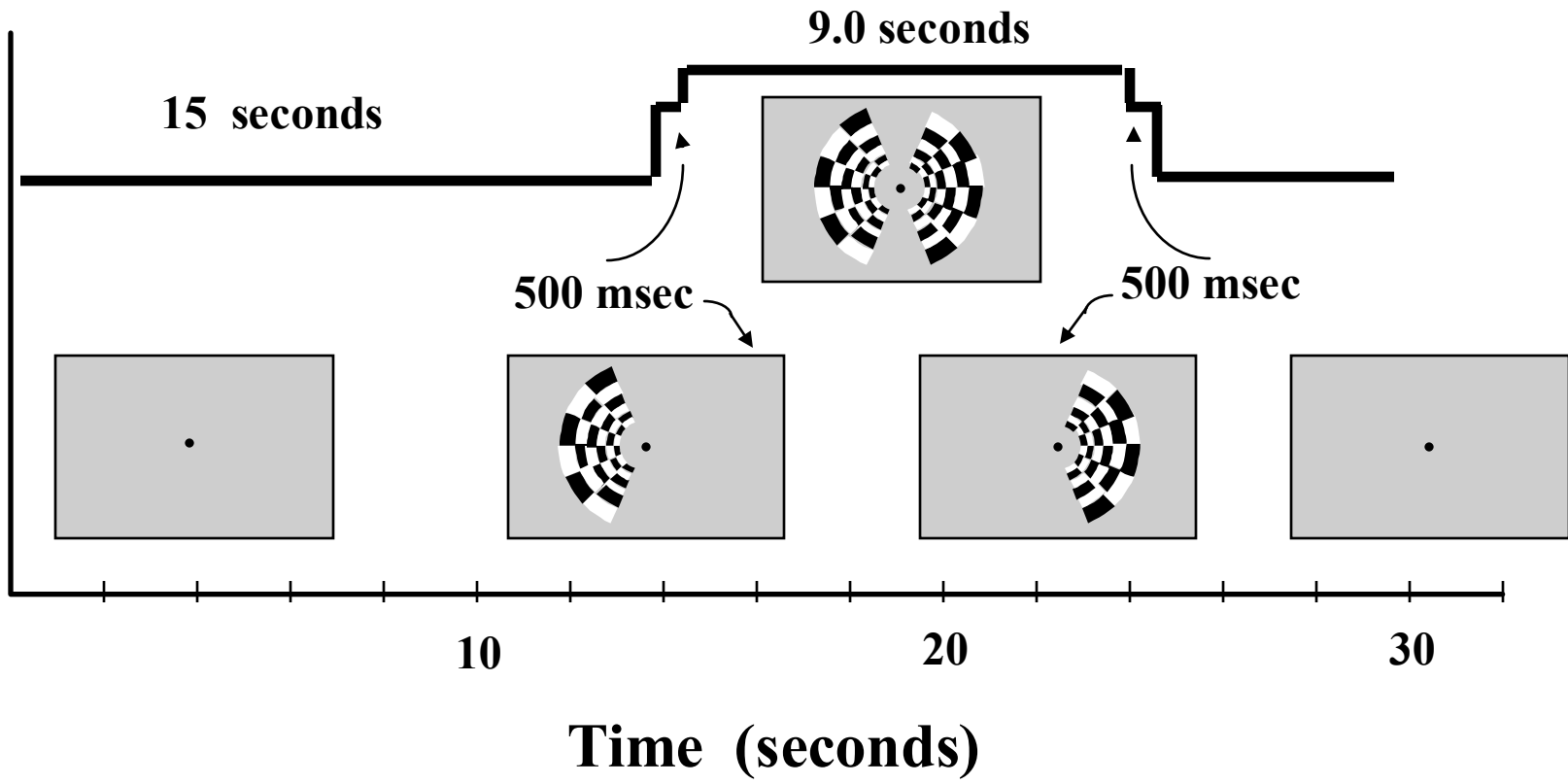
⁴Horton JC, et al. *Arch Ophthalmol* 108, 1025-31 (1990).

Regions of Interest Used for Hemi-Field Experiment

**Right
Hemisphere**

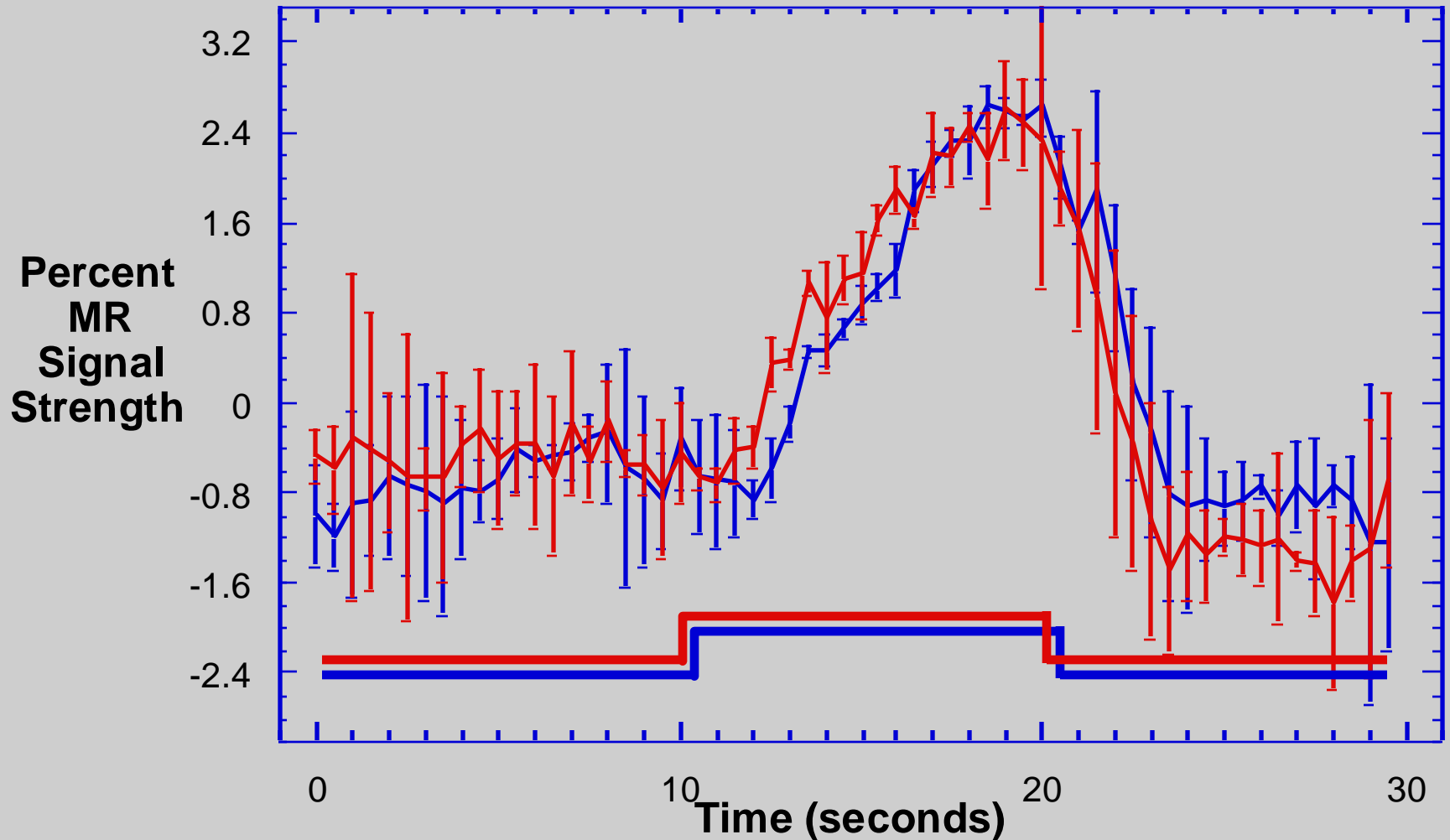


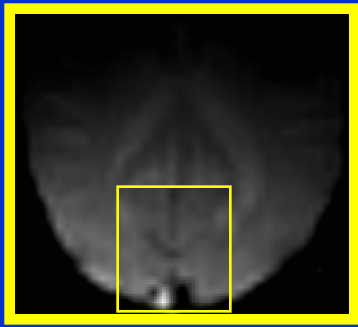
**Left
Hemisphere**




Hemi-field with 500 msec asynchrony

Average of 6 runs Standard Deviations Shown





500 ms



500 ms




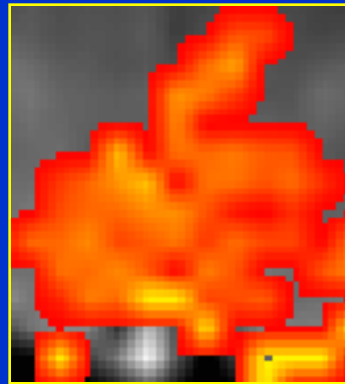
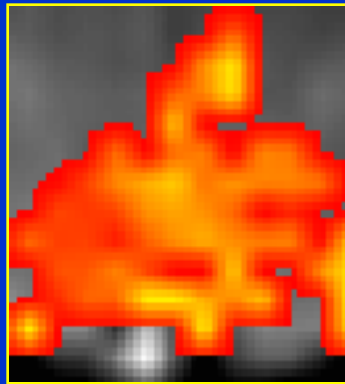

Right Hemifield

Left Hemifield

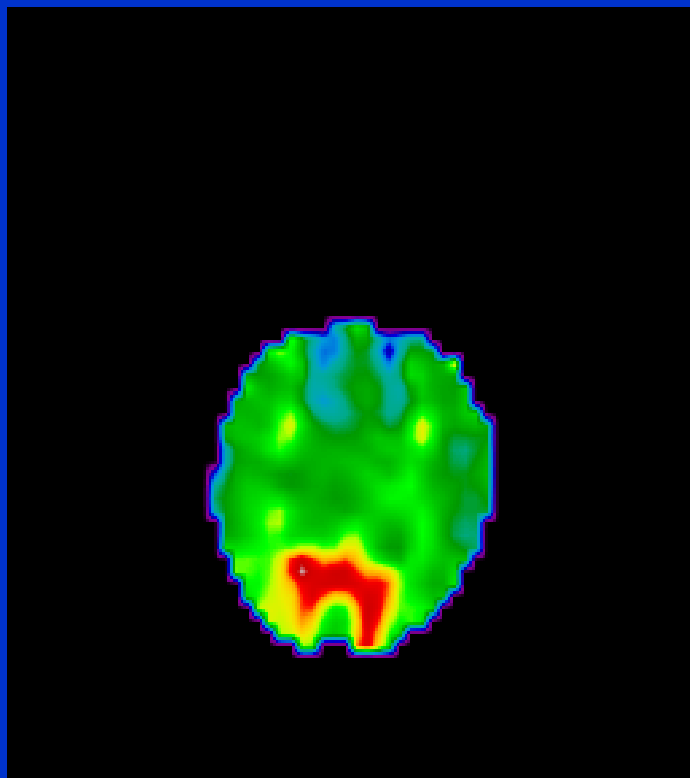
+ 2.5 s

0 s

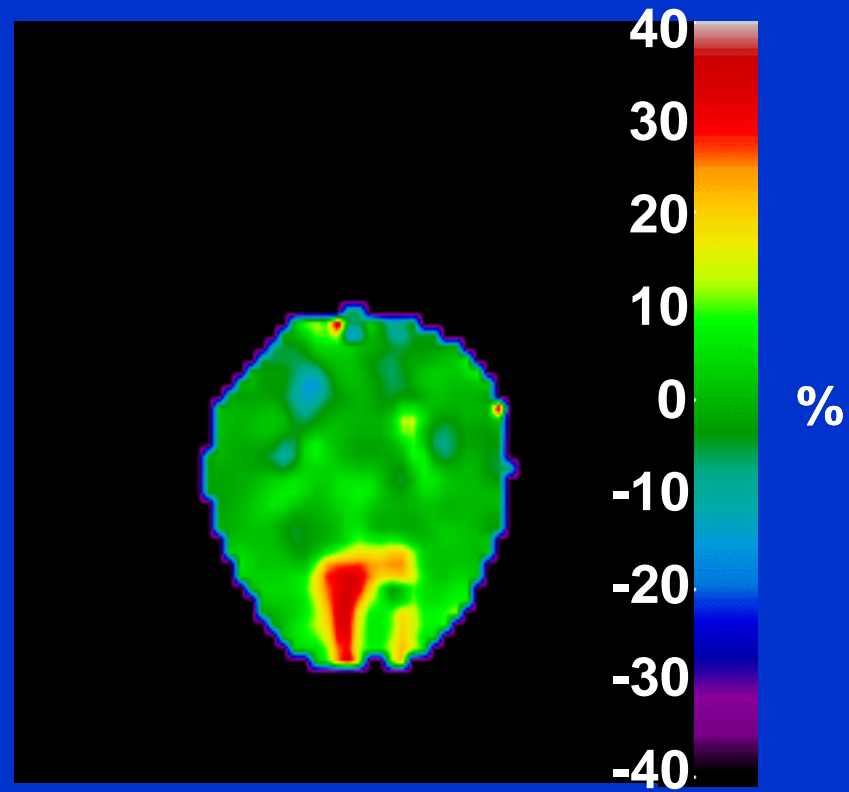
- 2.5 s



Computed CMRO₂ changes

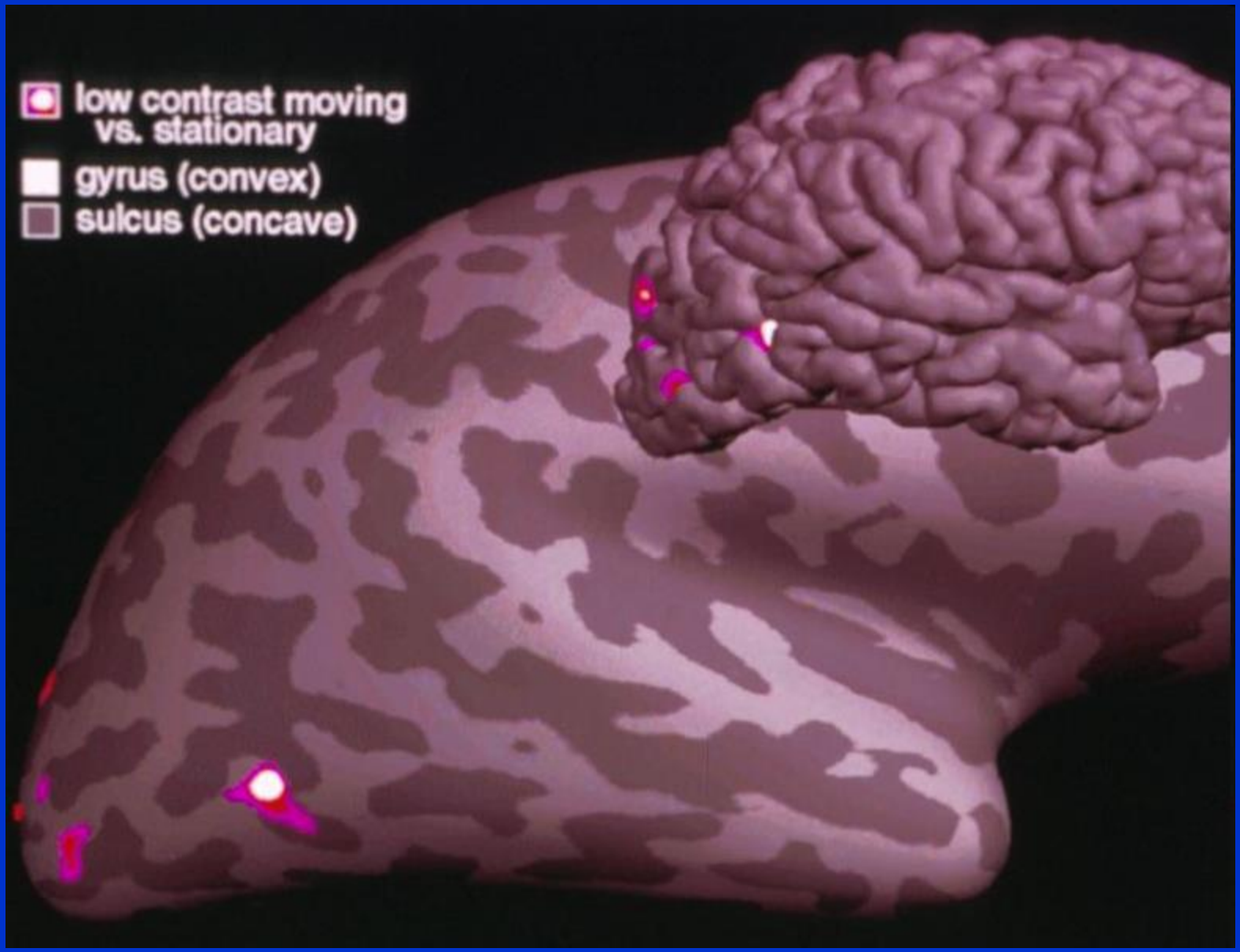


Subject 1

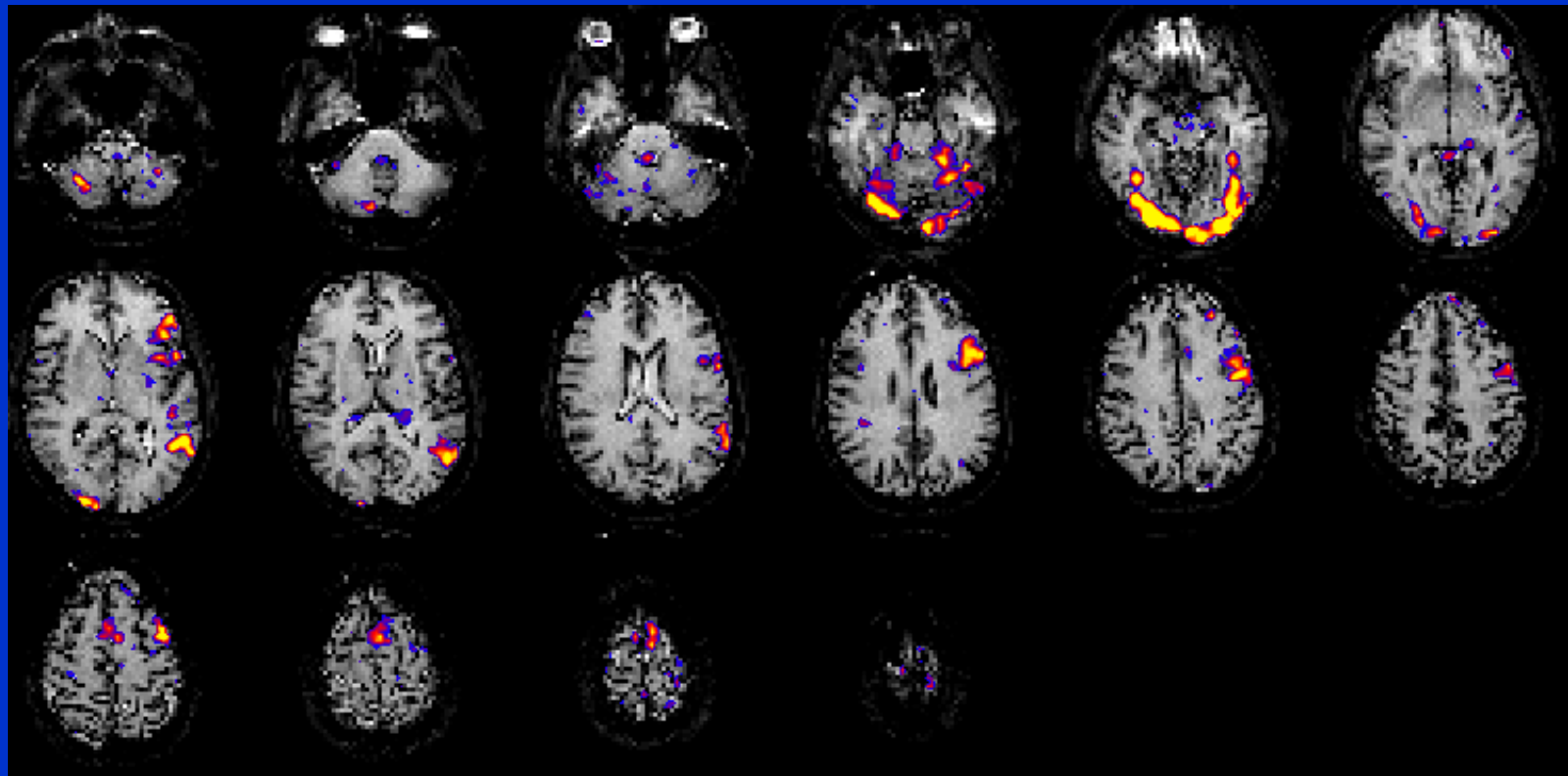


Subject 2

- low contrast moving vs. stationary
- gyrus (convex)
- sulcus (concave)

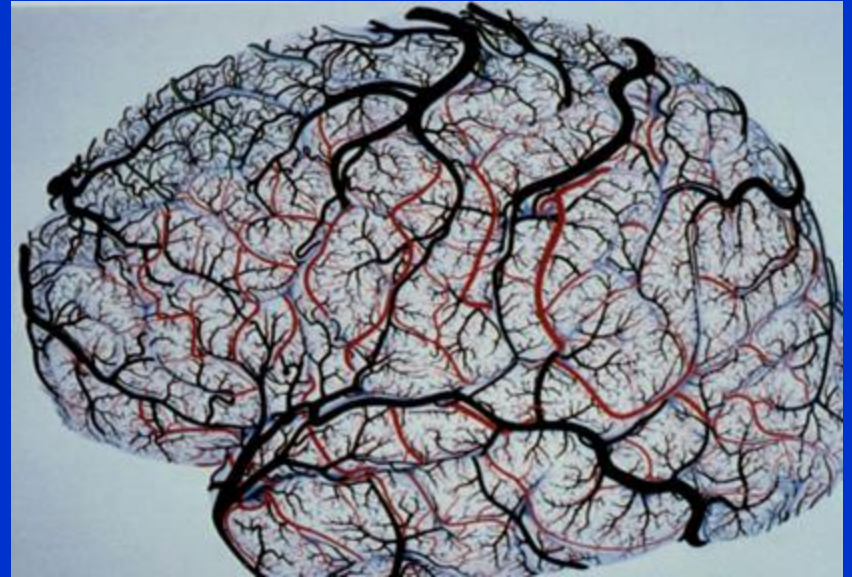


Word stem completion



A Primary Challenge:

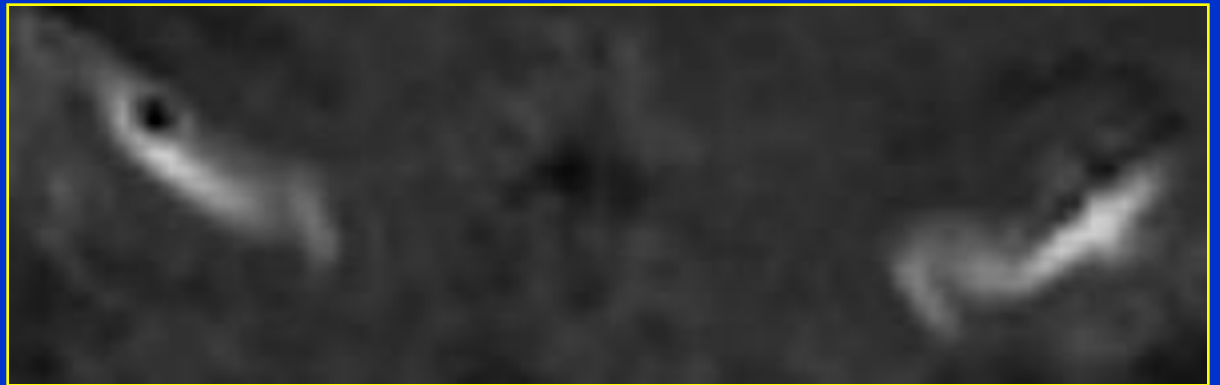
...to make progressively more precise inferences using fMRI without making too many assumptions about non-neuronal physiologic factors.



Anatomy



BOLD



Perfusion



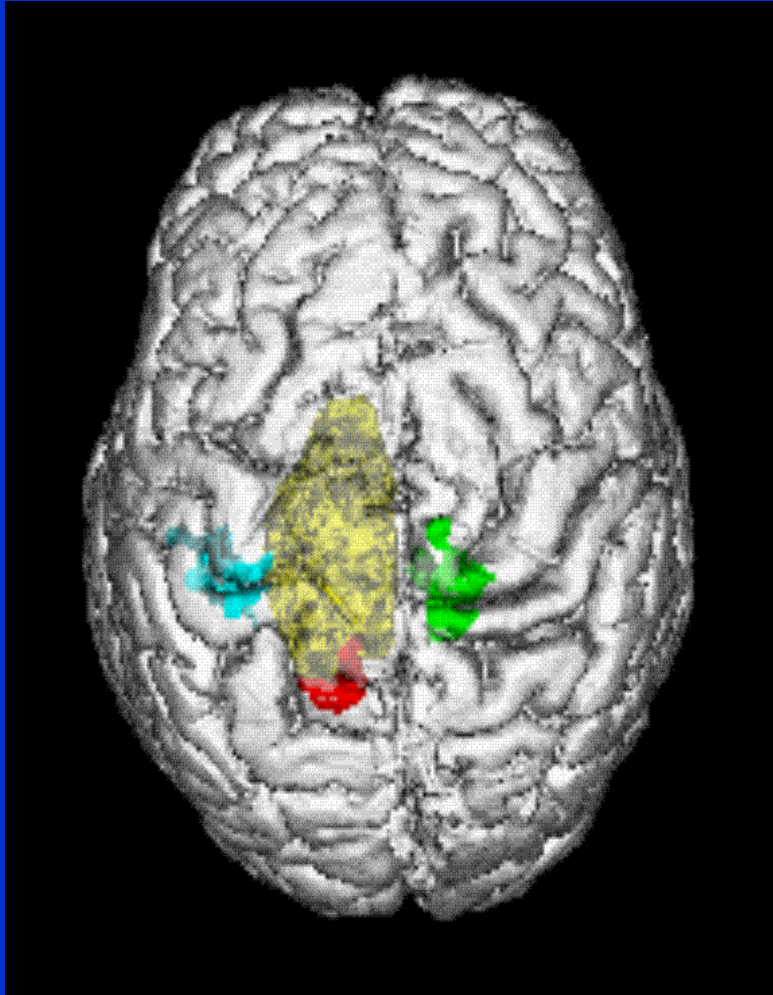
Presurgical Mapping

Left Foot

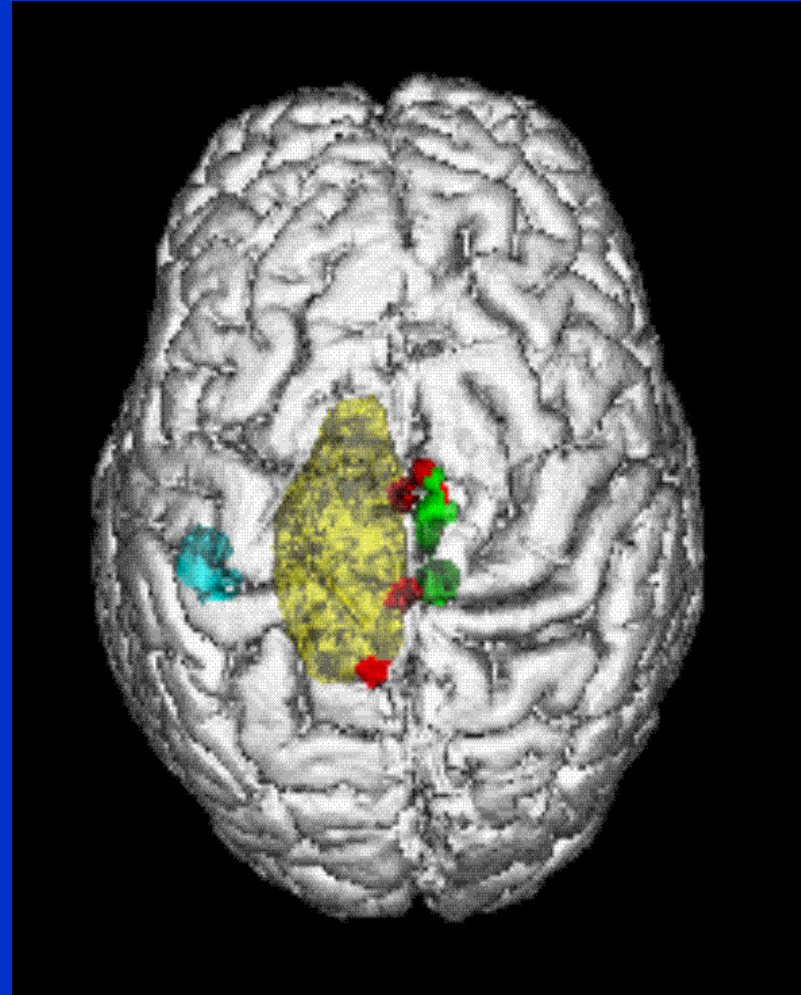
Tumor

Right Foot

Right Hand

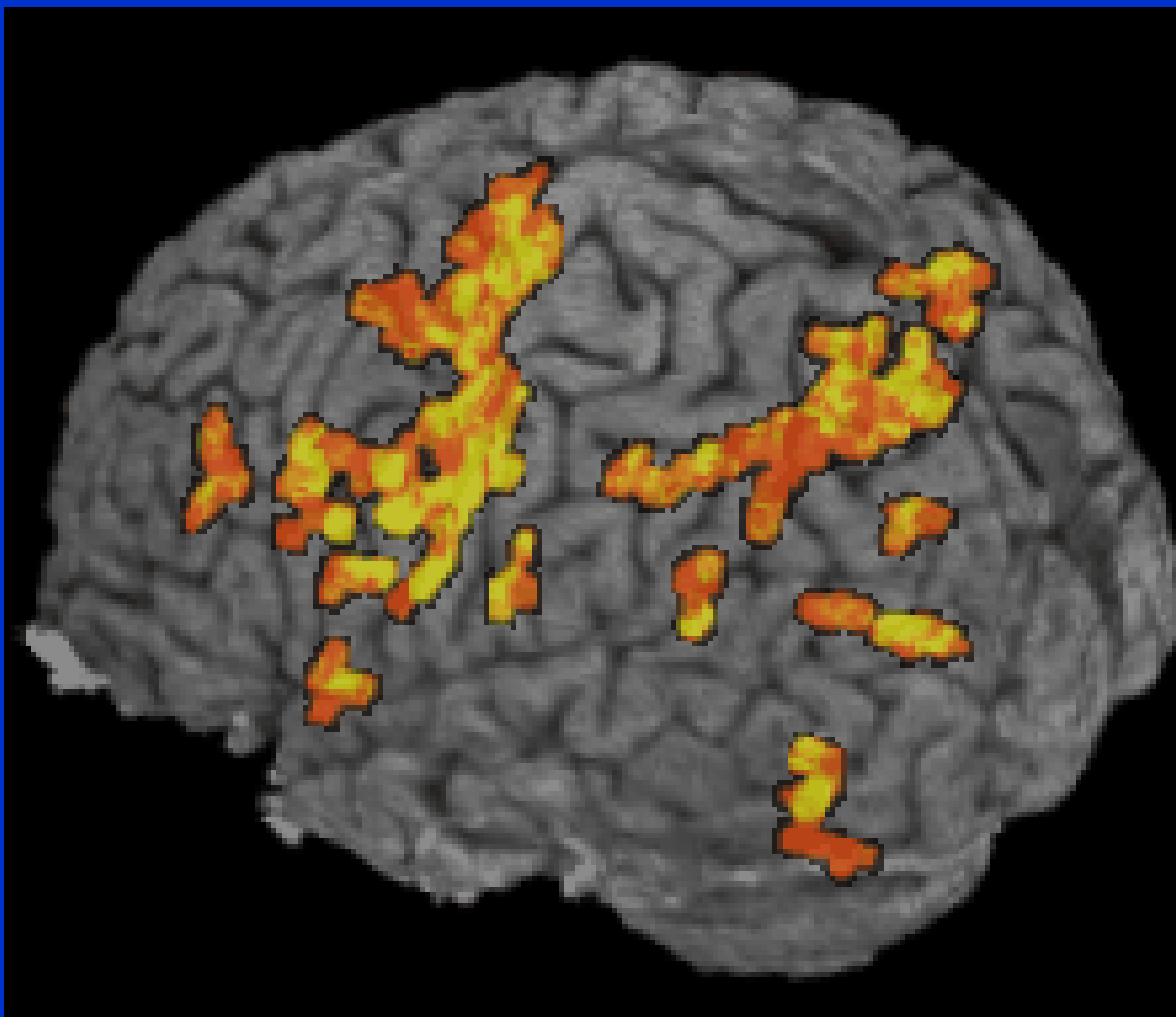


fMRI



O-15 PET

End of Acquisition



< 1 s to render

Blocked trials:

20 s on/20 s off

8 blocks

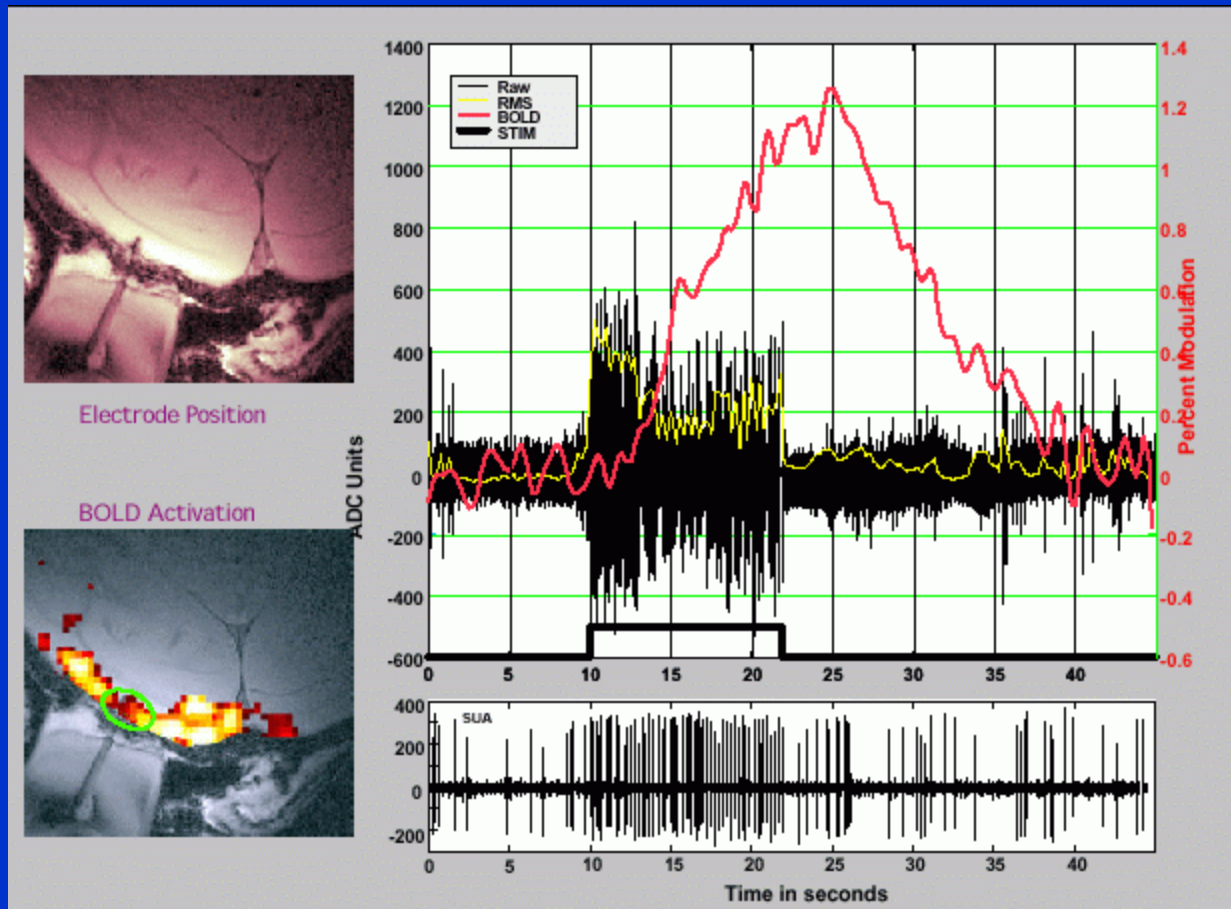
Blocks: 12345678

Color shows
through brain

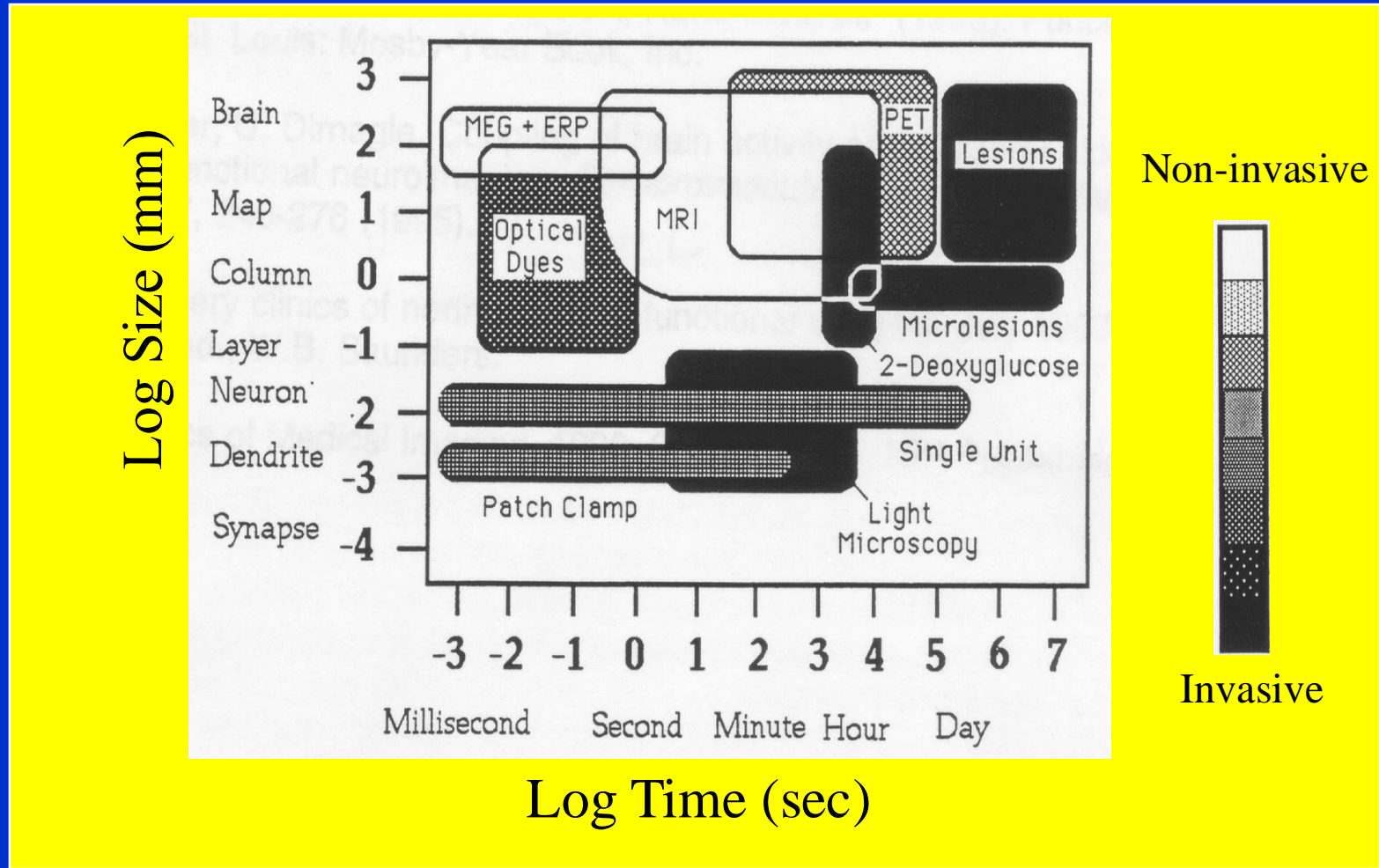
Correlation > 0.45

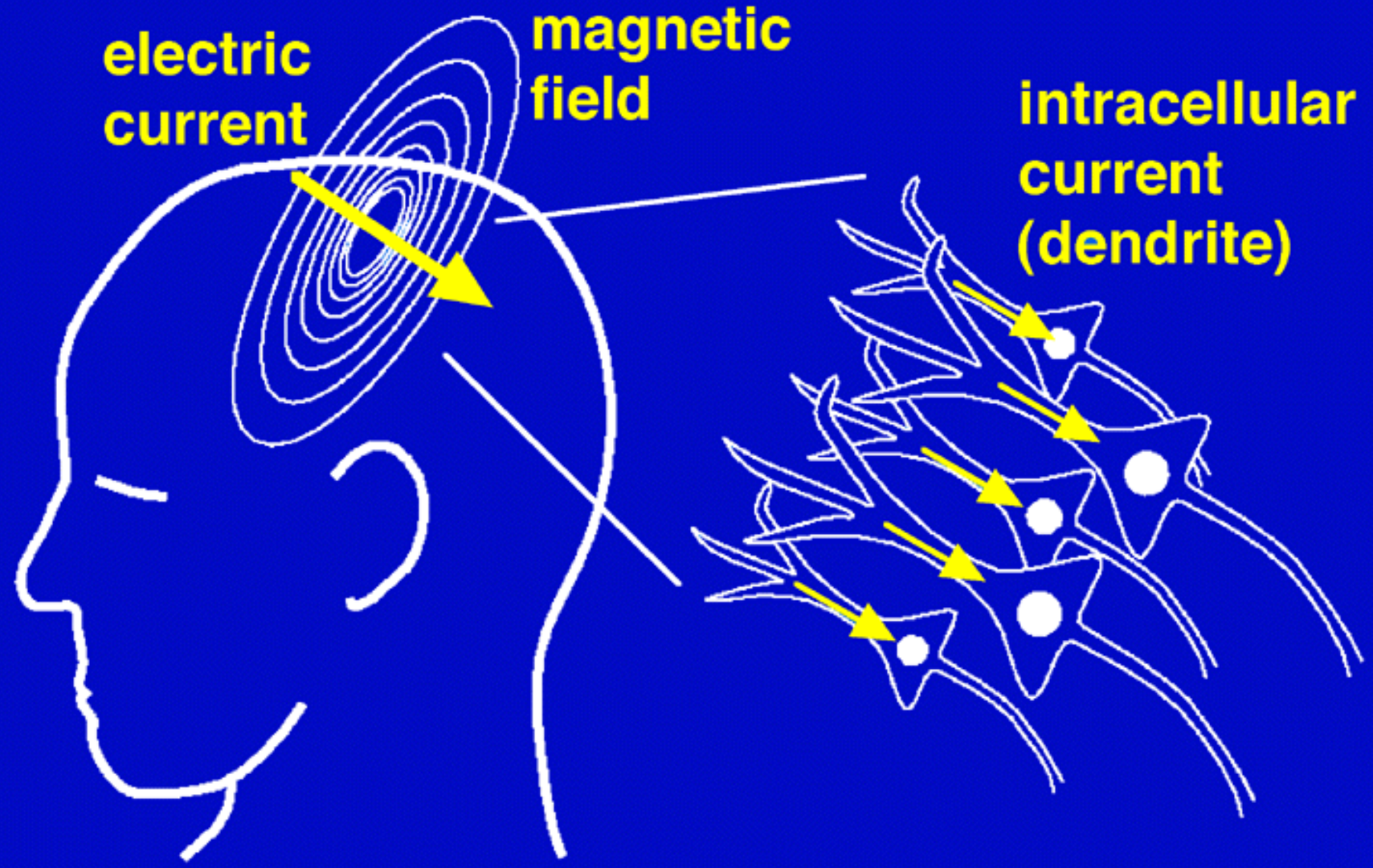
**The
End**

Combined Electrophysiological Measurement and fMRI

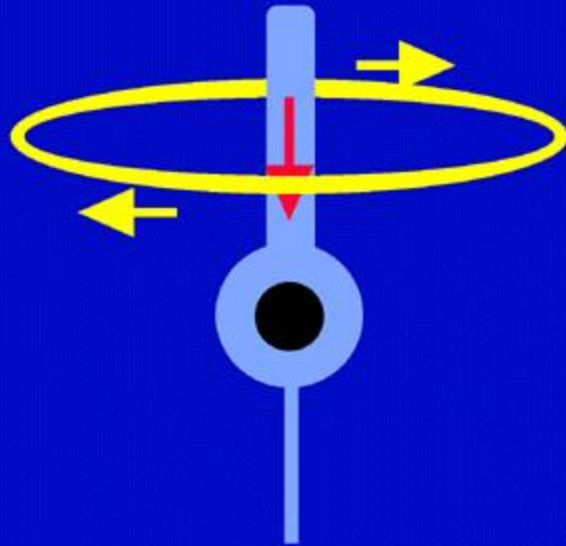


Functional Neuroimaging Techniques

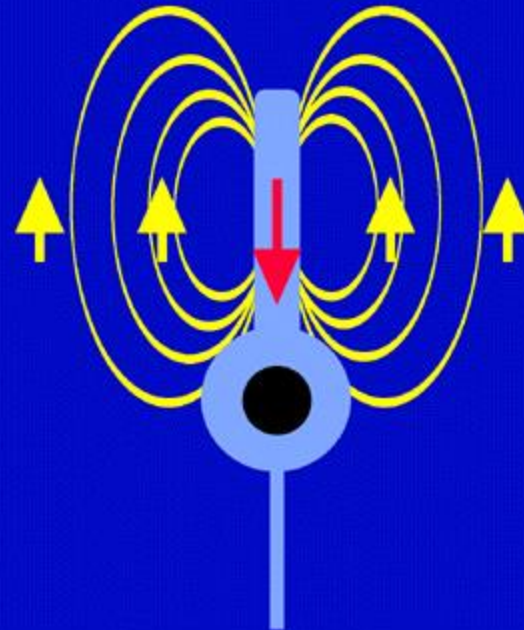




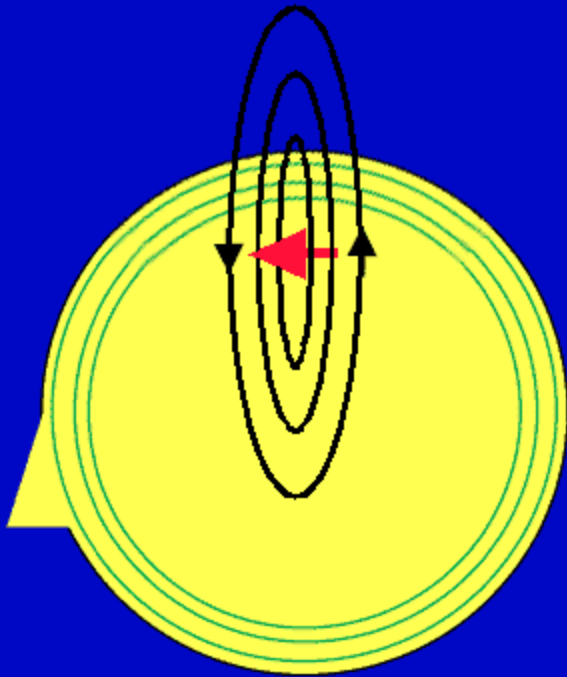
MEG:
intracellular
current



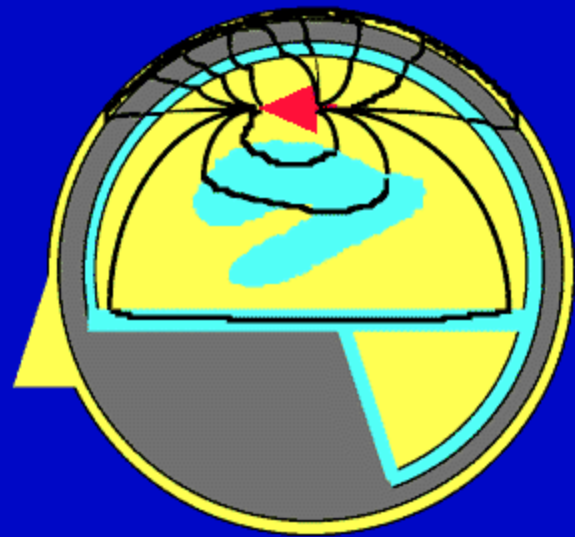
EEG:
extracellular
current

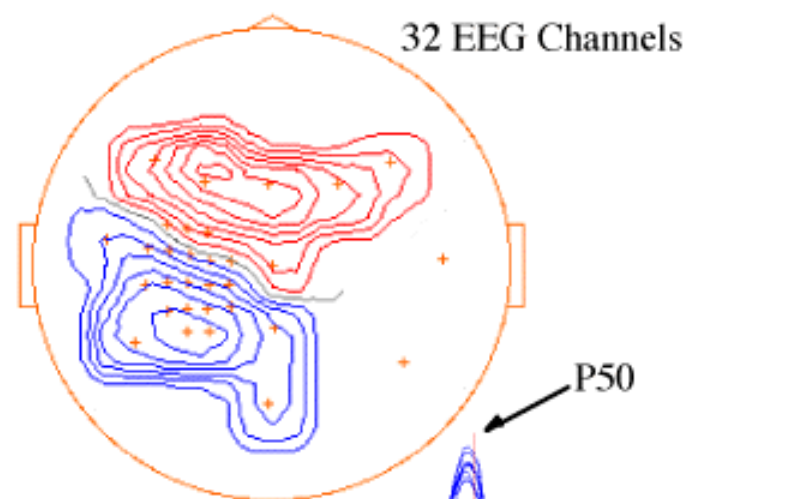
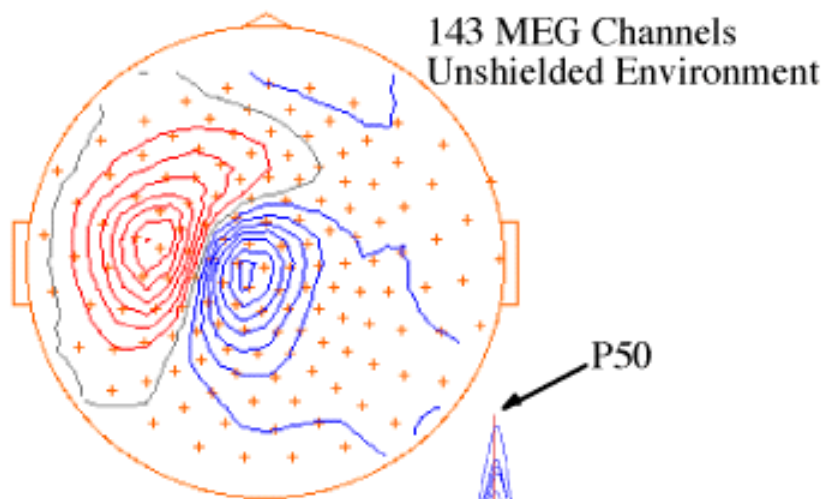


MEG



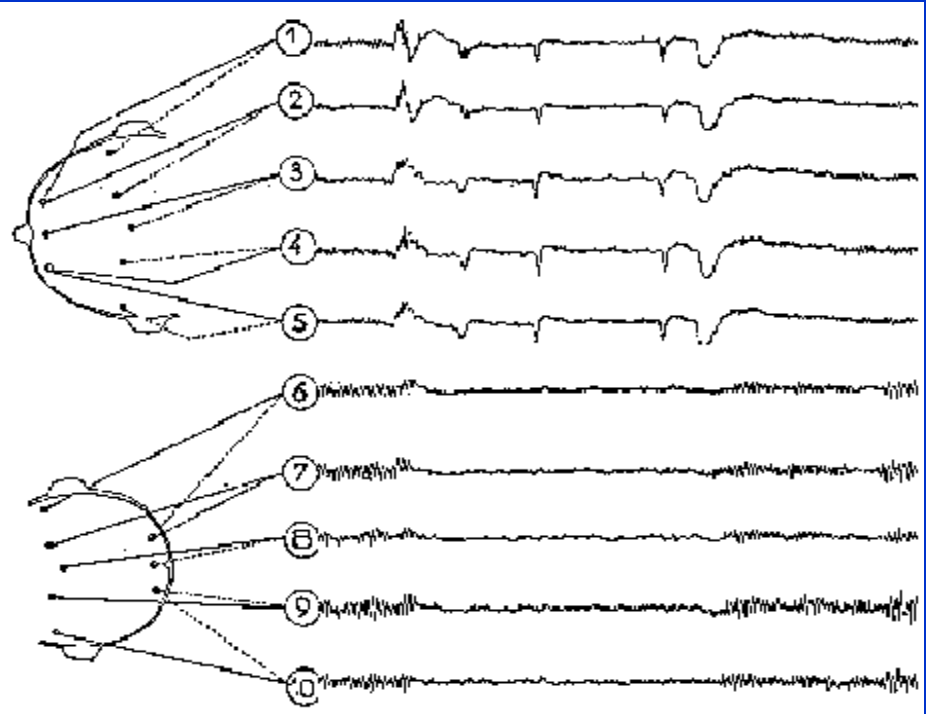
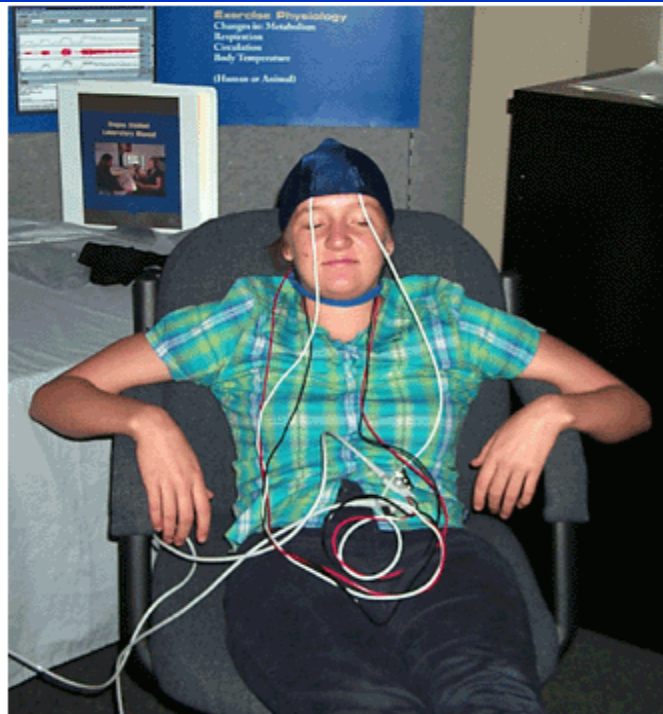EEG





Mechanical Stimulation
of Right Index Finger

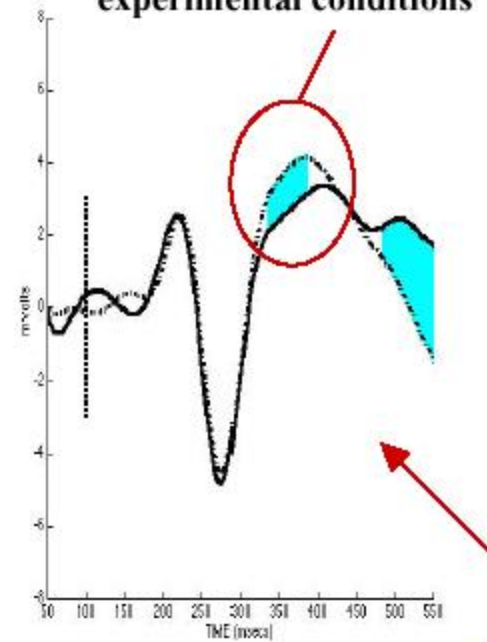
Mechanical Stimulation
of Right Index Finger



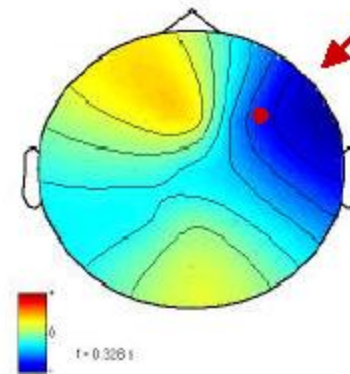
Electroencephalography (EEG) recording



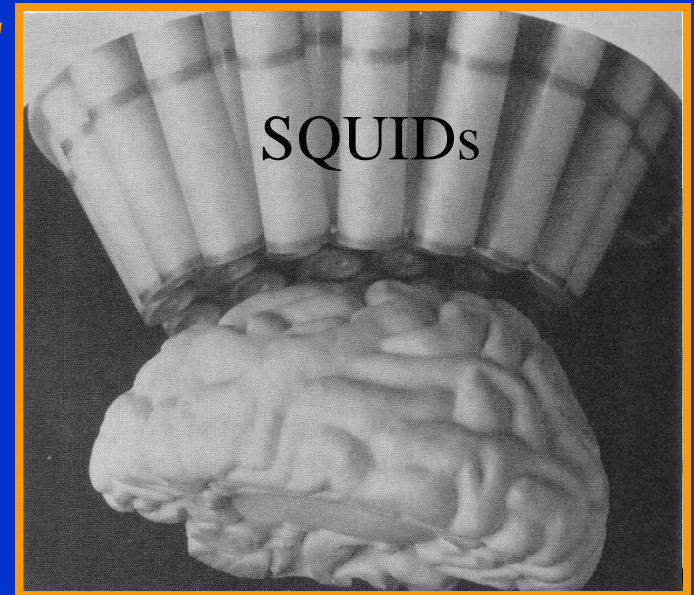
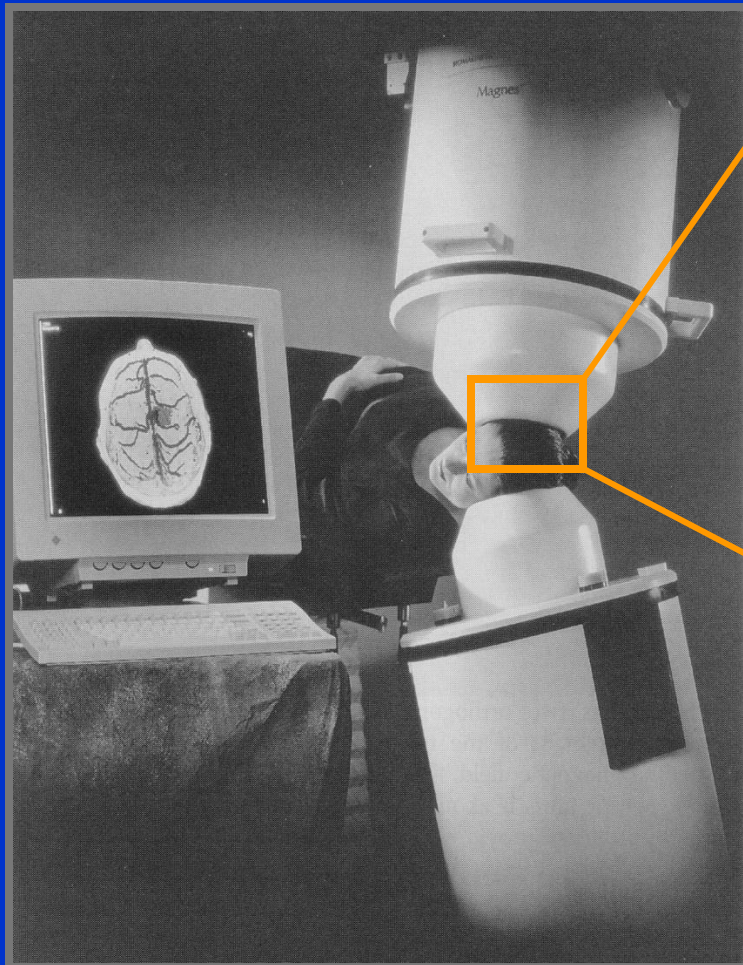
Statistical (T test) between two experimental conditions



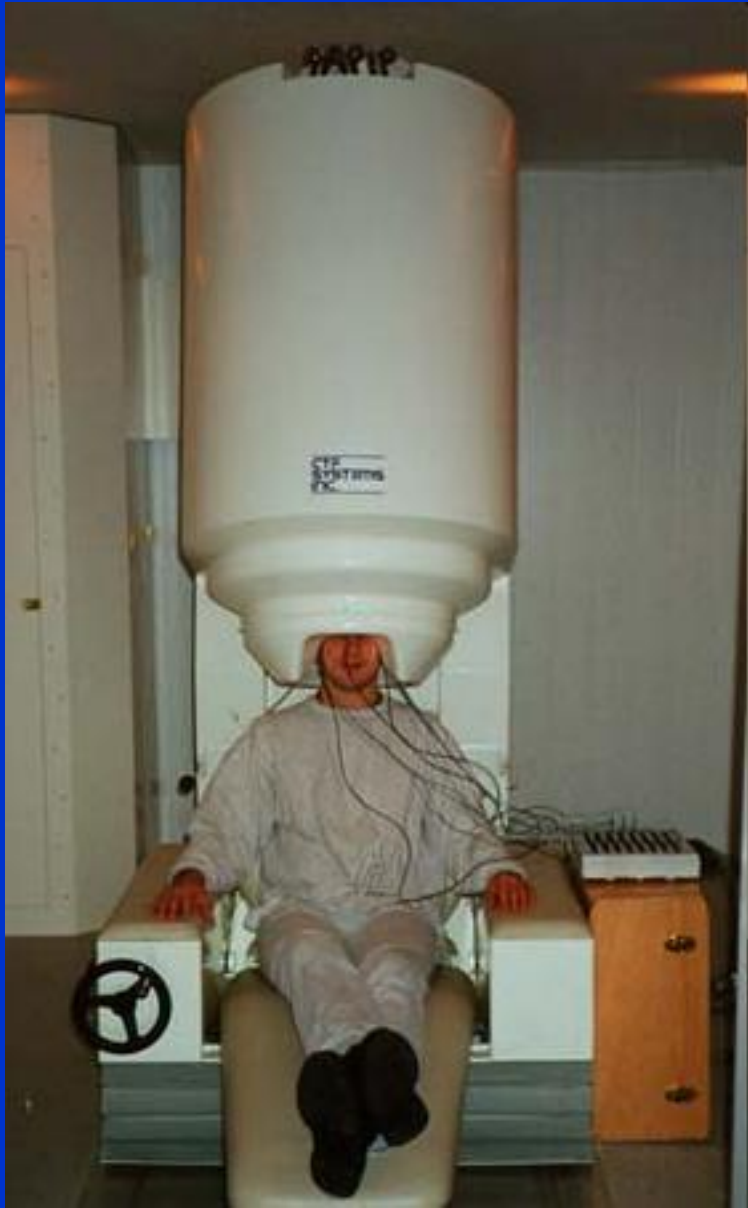F4



Magnetoencephalography (MEG)

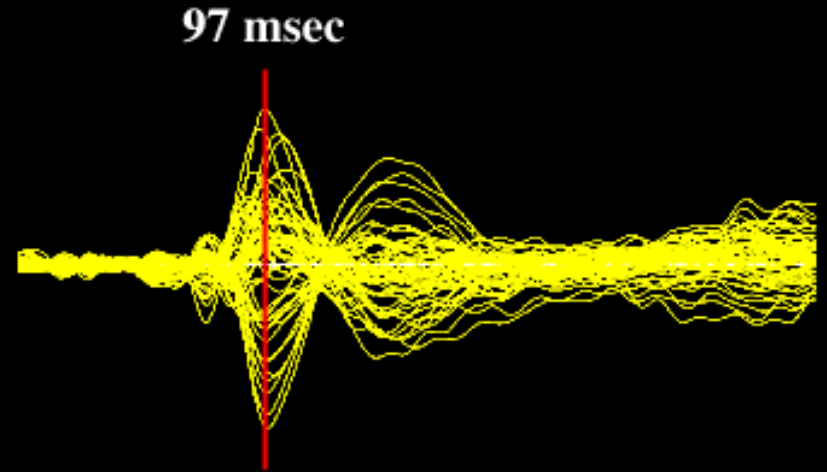
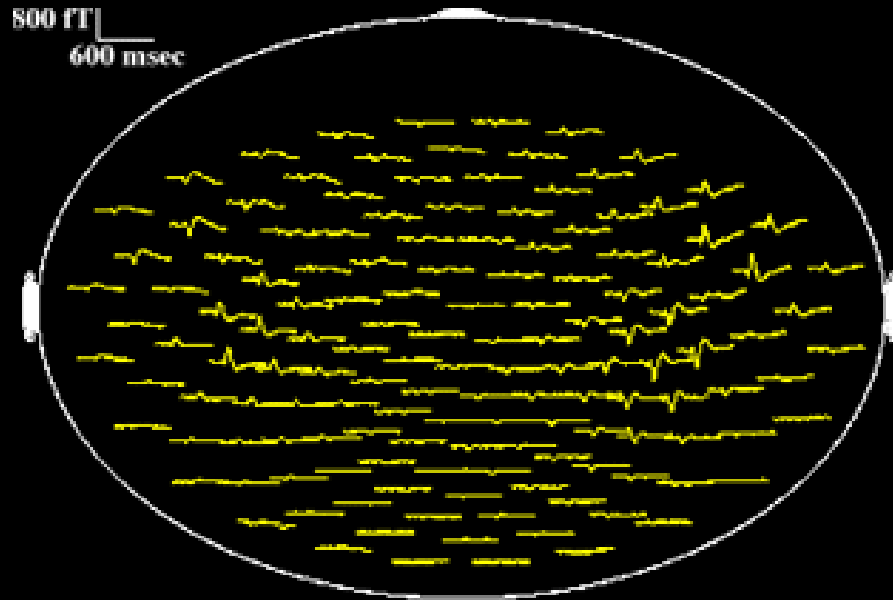


SQUID:
Superconducting Quantum
Interference Device



Combined MEG and EEG

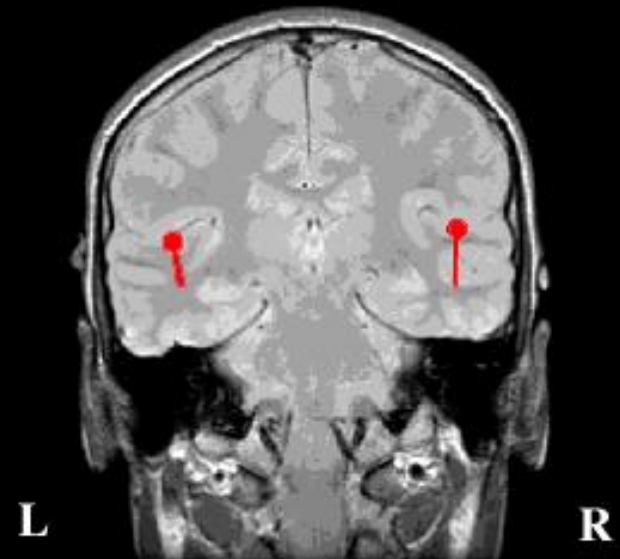
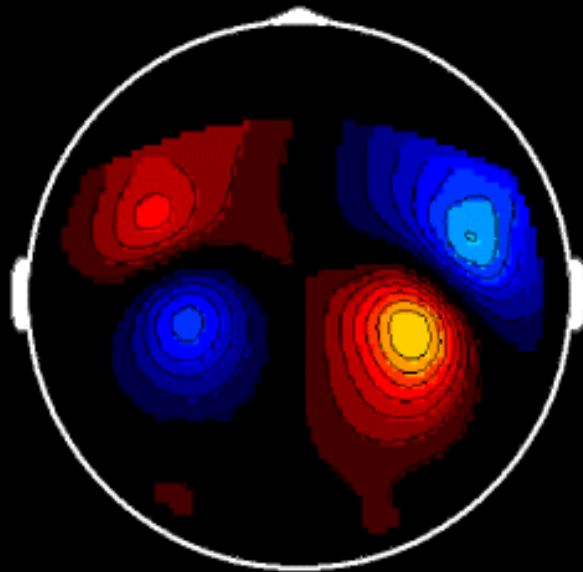
MEG Mapping



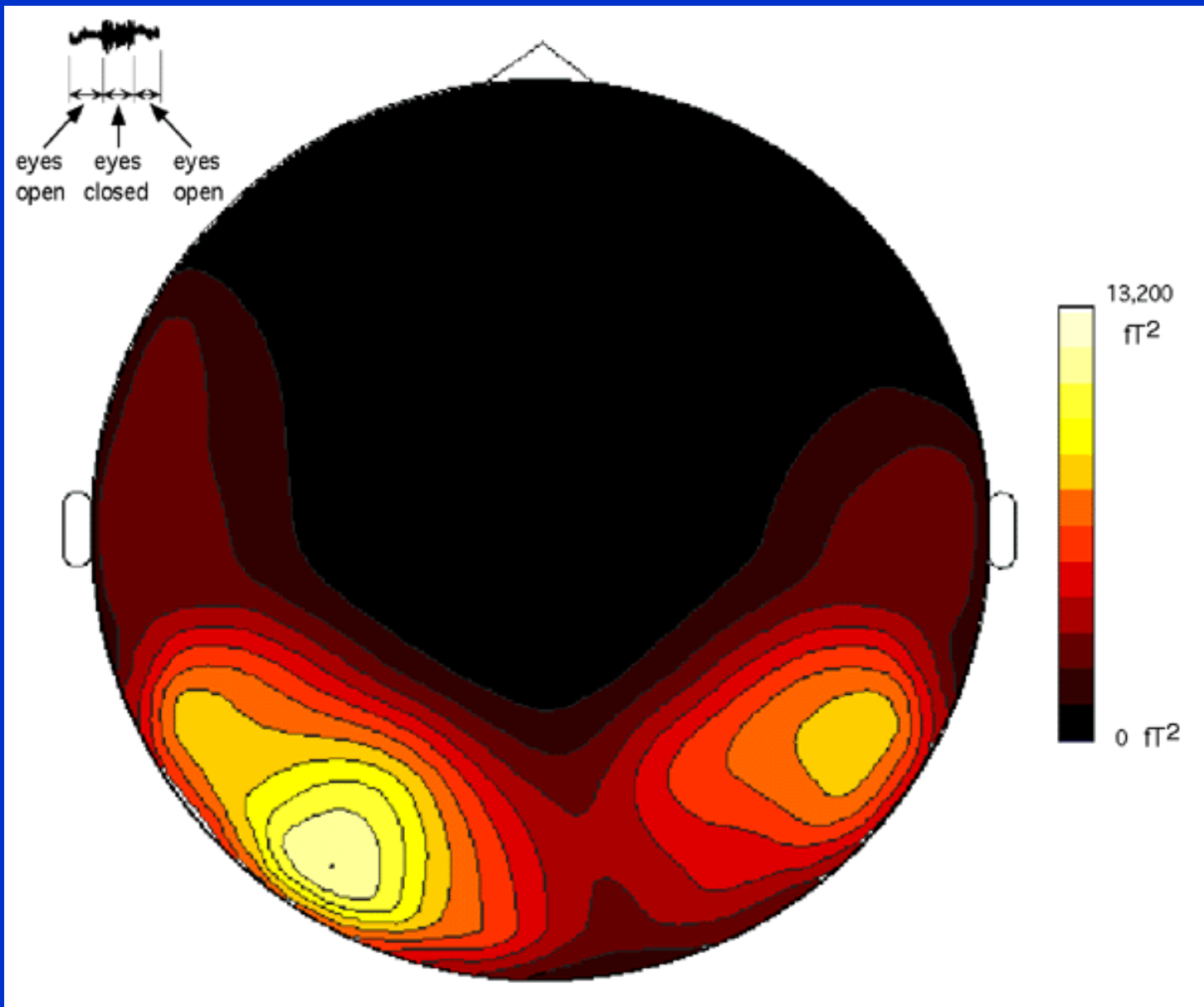
+360 fT



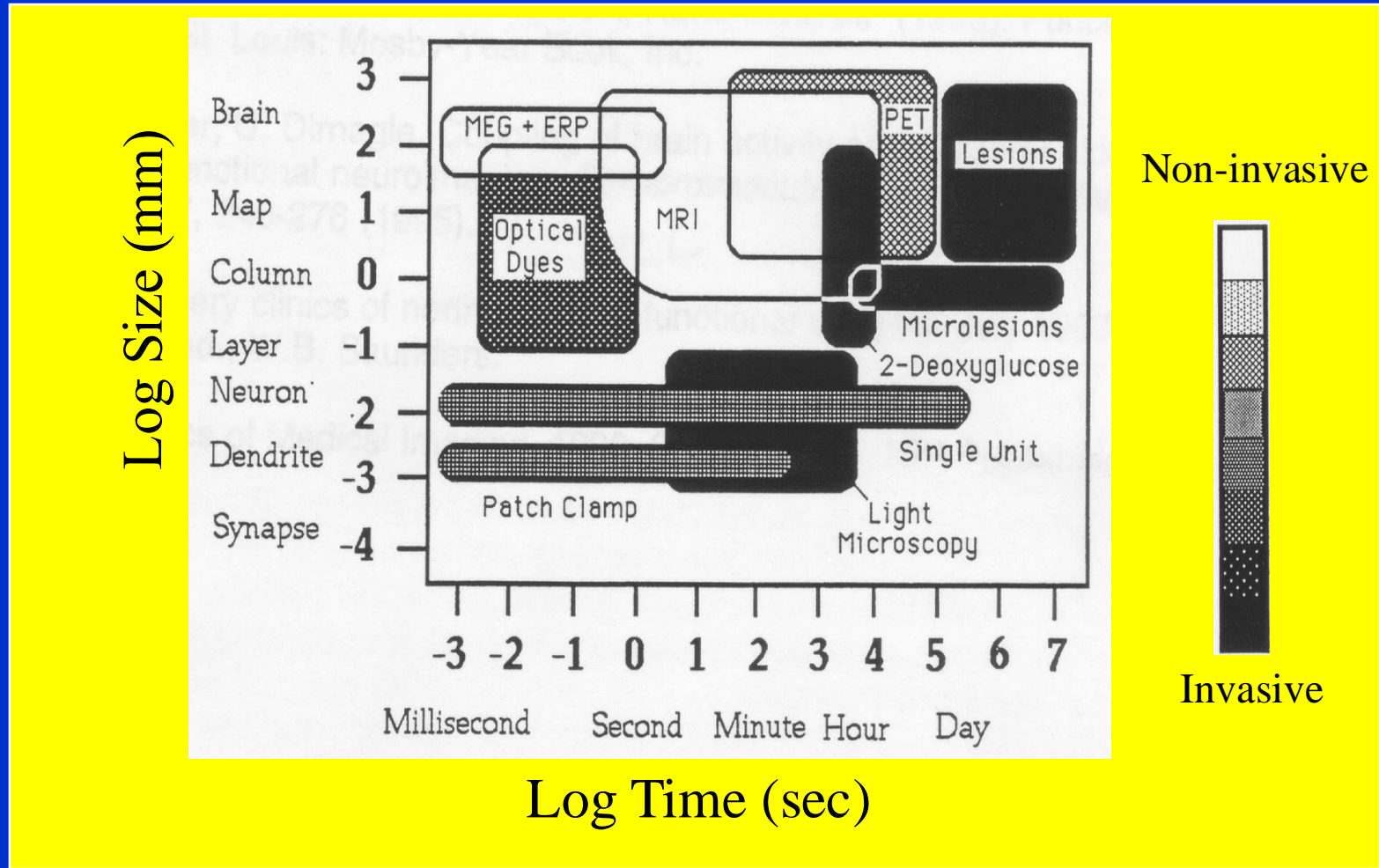
-360 fT



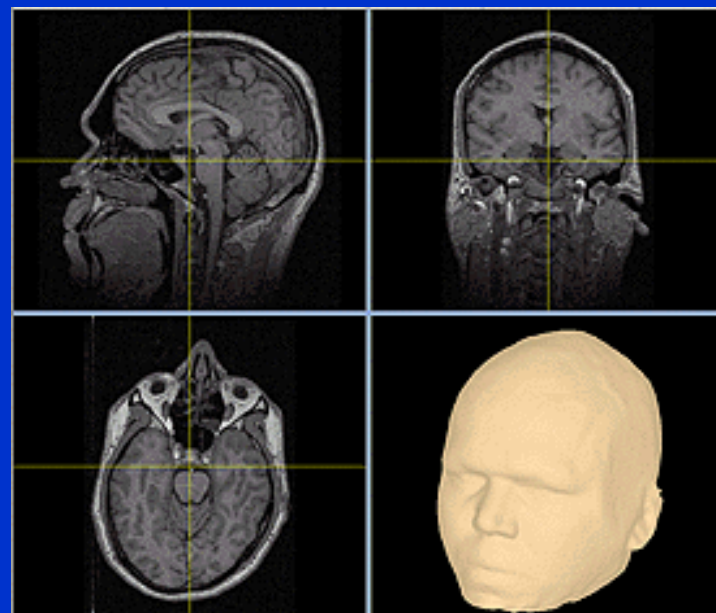
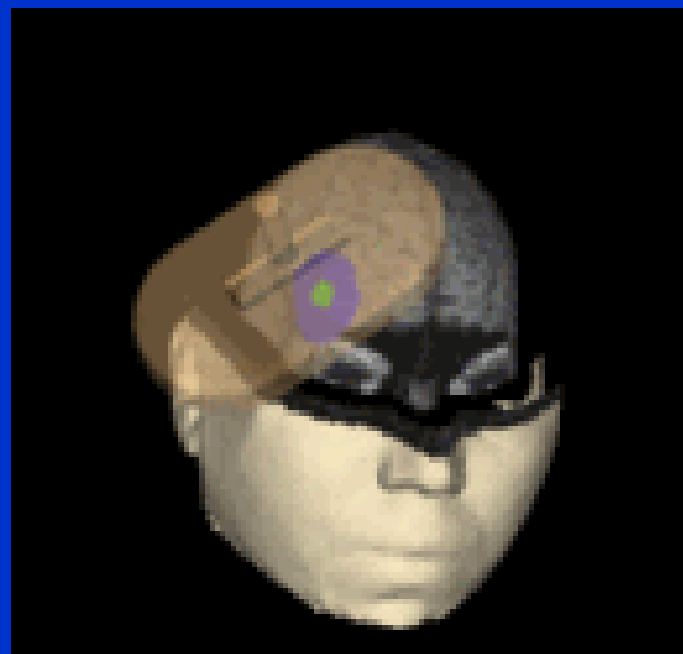
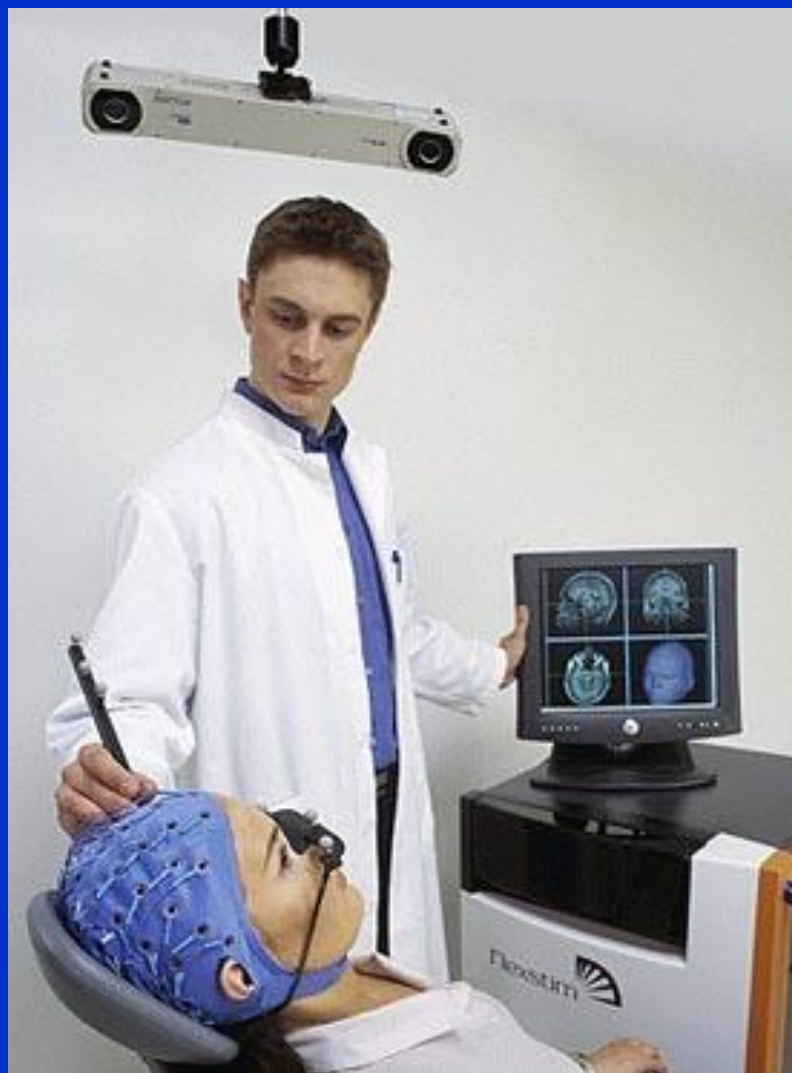Alpha Wave Activity Mapped with MEG



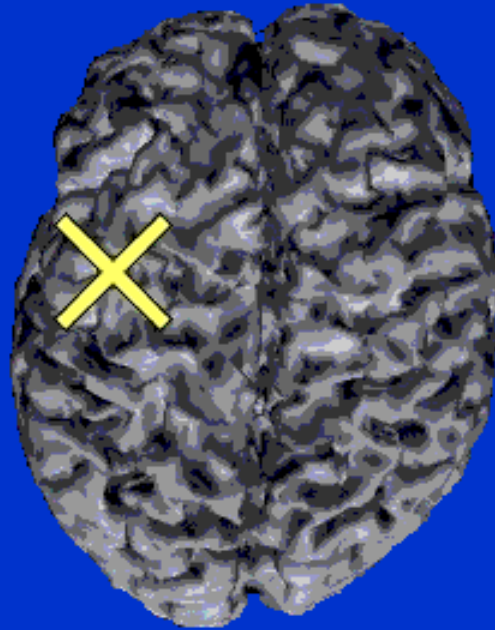
Functional Neuroimaging Techniques



Transcranial Magnetic Stimulation



Transcranial Magnetic Stimulation (TMS)



Acknowledgements

Ted Deyoe, **Medical College of Wisconsin**
Kathleen Schmainda, **Medical College of Wisconsin**
Steven Rao, **Medical College of Wisconsin**
Robert Savoy, **Massachusetts General Hospital**
Roger Tootell, **Massachusetts General Hospital**
Bradley Bookbinder, **Massachusetts General Hospital**
Randy Buckner, **Washington University, St. Louis**
Robert Innis, **National Institute of Mental Health**
Richard Coppola, **National Institute of Mental Health**
Sosumu Mori, **Johns Hopkins University**
Robert Cox, **National Institute of Mental Health**
Ziad Saad, **National Institute of Mental Health**
Eric Wong, **University of California, San Diego**
Ravi Menon, **University of Western Ontario**
Nikos Logotheddis, **Max Plank Institute, Germany**

FIM Unit & FMRI Core Facility

Director:

Peter Bandettini

Staff Scientists:

Sean Marrett

Jerzy Bodurka

Frank Ye

Wen-Ming Luh

Computer Specialist:

Adam Thomas

Post Docs:

Rasmus Birn

Hauke Heekeren

David Knight

Patrick Bellgowan

Ziad Saad

Graduate Student:

Natalia Petridou

Post-Back. IRTA Students:

Elisa Kapler

August Tuan

Dan Kelley

Visiting Fellows:

Sergio Casciaro

Marta Maieron

Guosheng Ding

Clinical Fellow:

James Patterson

Psychologist:

Julie Frost

Summer Students:

Hannah Chang

Courtney Kempes

Douglass Ruff

Carla Wettig

Kang-Xing Jin

Program Assistant:

Kay Kuhns

Scanning Technologists:

Karen Bove-Bettis

Paula Rowser

